



Dose-dependent effect of *Scolymus hispanicus* L. (sevketibostan) on ethylene glycol-induced kidney stone disease in rats

N Kamer Coşkun¹, Ali Coşkun², Busra Ertas¹, Sarfraz Ahmad^{3*}, Mehmet Ümit Özdöl⁴, Soner Çankaya⁵, Yeliz Çetinkol⁶, Yahya Ozel⁷ & H Kübra Elçioğlu^{1*}

¹Department of Pharmacology, School of Pharmacy, Marmara University, Istanbul-34722, Turkey

²Clinical Biochemistry Laboratory, Ozel Unye Cakirtepe Hospital, Unye/ORDU-52300, Turkey

³AdventHealth Medical Center, Orlando, FL 32804, USA

⁴Department of Pathology, Unye State Hospital, Unye/ORDU-52300, Turkey

⁵Faculty of Yasar Dogu Sport Sciences, Sports Management, Ondokuz Mayıs University, Atakum/SAMSUN-55270, Turkey

⁶Faculty of Medicine, Department of Basic Medical Sciences, Medical Microbiology, Ordu University, Altınordu/ORDU-52200, Turkey

⁷General Surgery Clinic, Umraniye Research and Training Hospital, Istanbul-34766, Turkey

Received 17 August 2021; revised 29 December 2021

Kidney stone, also known as calcium oxalate nephrolithiasis, is one of the most common diseases worldwide. Calculi usually forms when urine becomes supersaturated with particular calcium salts such as calcium oxalate. In the present study, we investigated the ameliorative potential of the root extract of the Common golden thistle, *Scolymus hispanicus* L. (SH) on rats with ethylene glycol (EG) induced kidney stone disease. Sprague-Dawley rats, each weighing 250-300 g, were divided into three groups (n=6 per group): (i) Control (C); (ii) EG; and (iii) EG+SH. To induce nephrolithiasis, the rats received 1% of EG with drinking water, while the C group received normal drinking water during the study. SH extract 2 g/kg was added to the treatment from the 4th week onwards in EG+SH group. At the end of each experiment, rats were decapitated and serum levels of calcium, magnesium, phosphorus, creatinine, aspartate aminotransferase (AST), alanine aminotransferase (ALT) and alkaline phosphatase (ALP) were assessed in all groups at 0, 4, and 8 weeks. Oxalic acid and creatinine levels were measured in urine samples collected at 24 h in metabolic cages. Renal tissues were evaluated histopathologically at the end of the experiment. After 8 weeks, serum creatinine levels were found decreased in the SH group while increased in the EG group. Serum magnesium and AST levels were also found decreased in the EG group, however, SH treatment reversed these values. The SH treatment also increased urinary oxalic acid levels. When the kidney tissue of EG group was examined, there was a high level of crystal/stone, especially in the renal cortex. In kidney tissues of the SH group, only small amounts of crystal/stone were observed. Our experimental findings have demonstrated the ameliorative potential of the aqueous extracts of *S. hispanicus* roots and shells on EG-induced in the kidney stones in rats. Isolation of active compounds of SH would be desirable to understand the biochemical mechanism behind the process better.

Keywords: Calcium oxalate, Common golden thistle, Crystal stone formation, Kidney tissue, Nephrolithiasis, Spanish oyster thistle

Nephrolithiasis, known as kidney or renal stone disease, has multifactorial pathology which has not been fully elucidated yet¹. It is known for its fairly high incidence in the Western countries (e.g., Europe 5-9% and North America 12-15%) and in Eastern countries (about 5%)². The risk of kidney stone disease has been reported to be three-times higher in men than in women³. It has been suggested that chronic diseases such as obesity, diabetes mellitus, hypertension, and metabolic syndrome, are also associated with kidney

stone formation^{3,4}. In addition, some medications (such as acetazolamide, indinavir, triamterene, vitamin D supplementation, ceftriaxone, and quinolone) have been reported to cause kidney stone disease^{2,5,6}.

The stone formation mechanism is a highly complex process involving supersaturation of urine and various physicochemical changes. As a result of supersaturation, the solution precipitates in the urine and causes nucleation, and thereby crystallization after the aggregation process. The risk factors for crystallization vary greatly based on the level of stone formation causing components such as calcium, phosphorus, uric acid and oxalate in the urine. Approximately, 75-80% of kidney stones contain

*Correspondence:

E-mail: kubra.elcioğlu@marmara.edu.tr (HKE);
sarfraz.ahmad@adventhealth.com (SA)

calcium [calcium oxalate (CaOx) and calcium phosphate]; and the rest consists of uric acid, cystine, struvite and hydroxyapatite⁷⁻⁹. The presence of CaOx crystals in the renal cells leads to the rise of free radicals causing oxidative stress¹⁰. Increased reactive oxygen species (ROS) in renal tubular cells cause inflammation in the cell epithelium and remodeling of the tissue¹¹⁻¹³. Irregularities in mineral metabolism and impairment of antioxidant mechanism cause formation of CaOx stones affecting the kidney epithelial cells⁴.

For the treatment of kidney stones, different treatment approaches are applied depending on the area where the stone is located, its size, and the components from which it is formed. Pharmacologically, thiazide diuretics reduces calcium clearance directly; alkaline treatment with potassium citrate decreases calcium excretion and increases urinary citrate; and allopurinol prevents recurrent stone formation by decreasing uric acid excretion. In addition, febuxostat, terpene essential oil preparations and corticosteroids are also used to treat of kidney stone^{14,15}. Although significant advances towards the medications have been made for the treatment of kidney stone disease, no cost-effective and efficacious drug has been found yet¹⁶.

Medicinal plants are known to be suitable for developing effective drugs for kidney stone treatment because of their high efficacy, minimal side effects, and relatively low costs. Studies have reported that natural products prevent oxidative damage and kidney stone formation in renal cells due to CaOx crystals. *Scolymus hispanicus* L. (SH), commonly called 'the common golden thistle or Spanish oyster thistle', locally known as "sevketibostan or Sevket-I Bostanr" plant, is one of the most common wild vegetables in the Mediterranean countries. This traditional medicinal herb is known for its diuretic, depurative, digestive, choleric and lithiuretic effects. Roots, stems and leaves of SH are reported to contain tannins, α -tocopherol, β -carotene, terpenoids and flavonoids which enrich the plant with various phytochemical and pharmacological properties^{17,18}. SH is used as a medicine in kidney stone disease under the trade name "Lityazol Cemil", thanks to the antioxidant properties of flavonoids and β -carotene molecules¹⁸⁻²⁰. Antioxidants or the anti-inflammatory properties of SH extract have been reported in previous experimental diabetes studies; and reduce pelvic renal stone, ureteral stone, and bladder stone with its antispasmodic effect¹⁹⁻²³. However, there is no

study on the protective effect of SH on renal calculi deposition in animals. Therefore in this study, we investigated the ameliorative potential of SH extract by monitoring the biochemical and histopathological parameters in rats with kidney stone induced by 1% ethylene glycol (EG).

Materials and Methods

Materials

All chemicals and reagents used in the determination of blood and urine levels of AST, ALT, ALP, calcium, magnesium, phosphorus, and creatinine, etc. were purchased from Elabscience (Houston, TX, USA) and bt Products (Izmir, Turkey).

Plant material and preparation of *S. hispanicus* extract

Root and shell parts of *S. hispanicus* plant were obtained from Samsun Botafarma Health Products Company, Turkey. The plant roots and shells of 400 g were dried in an oven at 55-60°C. After drying, the remaining 20 g of the substance were grinded. Forty mL of 70% ethyl alcohol was added to 20 g of the substance and left for maceration. Then it was taken to the percolator where 2, 3, 4, 5 and 6 percolates of the six putative percolates were combined. The alcohol was evaporated, and with the extract remaining at the bottom of the beaker; it was joined to the 1st perched, and 20 mL of the extract was obtained.

Animals

All animal experiments were carried out with the approval of the Marmara University Animal Experiments Local Ethics Committee (Project No: 04.2017.mar). Adult male Sprague-Dawley rats (250-350 g) (n=6 in each experimental group) were obtained from Marmara University's Experimental Animal Implementation and Research Center. The rats were housed under controlled temperature (20-23°C), in humidity (40-60%), and light (12 h light/dark regime) regulated rooms. The animals were kept on a standard rodent pellet diet, with tap water available *ad libitum*.

Experimental design of the study

The animals were made into three groups (randomly n=6 per group) as: (i) the saline-treated control (Control); (ii) saline-treated with EG; and (iii) SH-treated with EG (EG+SH) groups. To induce nephrolithiasis, the rats received 1% of EG with drinking water, while the control group received normal drinking water during the study. Therapeutic group (EG+SH) was given 1% EG in their drinking

water for 8 weeks while the extract of SH at 2 g/kg was given to these rats by oral gavage from the 4th week until the end of the experiment.

Assessments of biochemical parameters

At the beginning of the experiment, and 4 & 8 weeks, the blood specimens were drawn from the experimental animals; which were centrifuged at 4000 rpm for 15 min. Blood levels of calcium, phosphorus, magnesium, creatinine, AST, ALT and ALP were measured utilizing appropriate biochemical assays. For this, bt Products[®] calcium, phosphorus and magnesium assay kits and Elabscience[®] creatinine, AST, ALT and ALP Rat ELISAKits, respectively, were used according to the kit manufacturers' procedures.

The urine of the experimental animals placed in 24 h metabolic cages were collected at the beginning of the experiment, and at the end of 4th and 8th week. Food and water were also kept in metabolic cages throughout the experiment. For analysis, 1 mL of urine samples were centrifuged at 2000 rpm for 5 min. Creatinine and oxalic acid levels in urine were determined utilizing Elabscience[®] Rat ELISA kit. In addition, the levels of leucyl aminopeptidases (LAP)

and gamma-glutamyl transferase (GGT) enzymes were measured utilizing Elabscience[®] LAP and GGT Rat ELISA kits.

Statistical analysis

The results are expressed as mean ± standard error of mean (SEM). The interactions between the different groups were tested using analysis of variance (ANOVA) with 95% confidence interval (CI) and Tukey's post hoc test. Statistical difference was considered significant at *P* < 0.05. The data were analysed using Graph Pad 9.0 software (Graph Pad, San Diego, CA, USA).

Results

In this study we investigated the effect of *Scolymus hispanicus* L. root and shell extract for potential treatment of kidney stone disease. No changes in the water and nutrient intakes were observed during the experimental study period. The body weights of the animals were measured at the beginning and at the end of the experiment. At the end of the experiment, there was no statistically significant increase in the weight of the animals in all cages (Fig. 1).

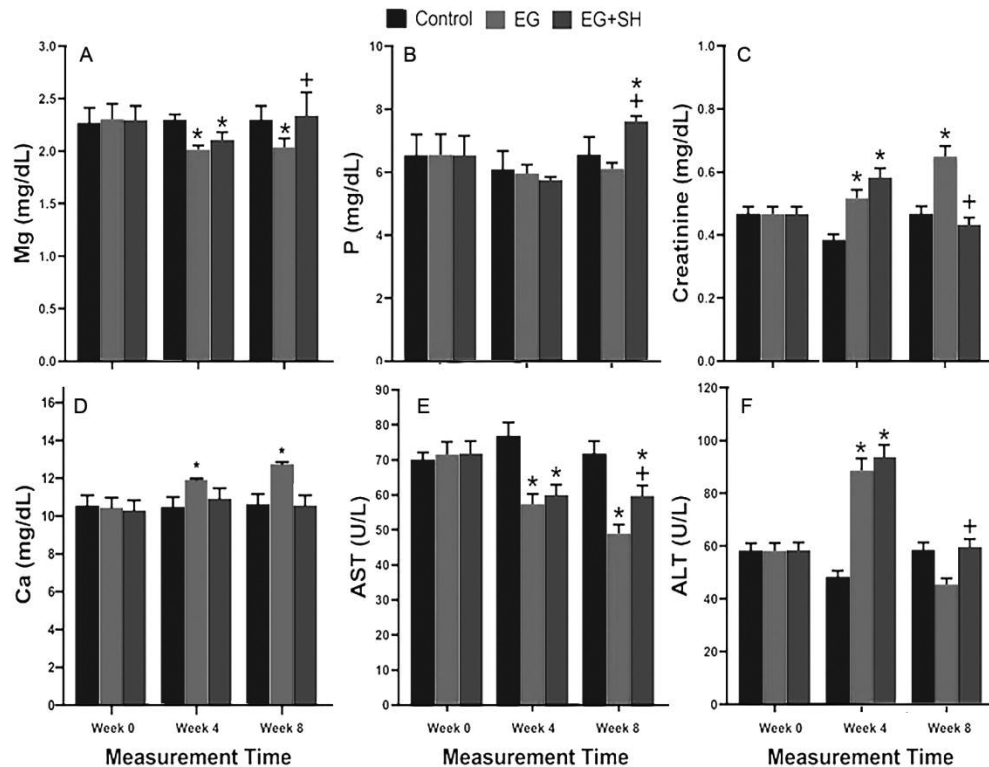


Fig. 1 — Measurement of blood serum levels of (A) magnesium; (B) phosphorus; (C) creatinine; (D) calcium; (E) aspartate aminotransferase (AST); and (F) alanine aminotransferase. [**P* < 0.05 compared to the control group and †*P* < 0.05 compared to ethylene glycol (EG) group. SH = *Scolymus hispanicus* L.]

Blood collection and parameters

In the first 4 weeks, magnesium levels decreased in the EG+SH treatment groups, whereas the EG group showed no change after 4 weeks. Magnesium levels increased significantly in SH treatment group ($P < 0.05$) and returned to control group levels (Fig. 1A). Serum phosphorus levels were significantly higher ($P < 0.05$) in the control and EG groups (Fig. 1B).

As shown in Figure 1C, serum creatinine levels of EG+SH group were decreased significantly ($P < 0.05$) as compared to the EG group. The creatinine levels of EG group continued to increase significantly ($P < 0.05$) as compared to the control group (Fig. 1C).

Serum calcium levels were significantly increased during the first 4 weeks in the EG group as compared to the control group, and continued to increase in the EG group at 8 weeks. At the end of SH treatment, calcium levels were close to the control group ($P < 0.05$) (Fig. 1D).

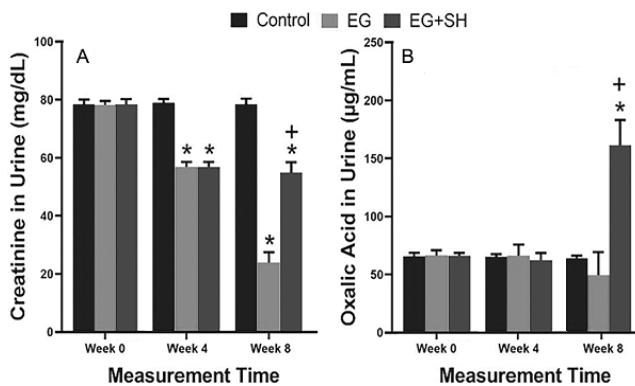


Fig. 2 —Levels of (A) Creatinine; and (B) Oxalic acid in urine samples of the three groups at the beginning and after 4th and 8th week of experiment. [* $P < 0.05$ compared to control group, + $P < 0.05$ compared to ethylene glycol (EG) group. SH = *Scolymus hispanicus* L.]

Serum AST levels decreased in the EG group and the first 4 weeks in SH group; however, no further decrease was noted after starting the SH treatment. At the end of the treatment, AST levels in the SH group were significantly higher ($P < 0.05$) than in the EG group and were significantly lower ($P < 0.05$) than the control group (Fig. 1E).

Serum ALT levels were significantly increased ($P < 0.05$) during the first 4 weeks in EG group, and a decrease was seen after 4 weeks. At the end of the experiment, serum ALT levels of the SH treatment group were found to be increased significantly ($P < 0.05$) as compared to the EG group (Fig. 1F).

Urine collection and parameters

When creatinine levels in the urine samples were examined, a significant decrease was observed in the EG group ($P < 0.05$), whereas in the SH treatment group, it decreased after 4 weeks. At the end of the experiment, creatinine levels of the EG+SH treatment group was significantly higher than in the EG group ($P < 0.05$); and a significant decrease ($P < 0.05$) was found when compared to the control group (Fig. 2A). At the end of the experiment, the level of oxalic acid in the urine samples increased significantly ($P < 0.05$) as compared to the EG and control groups in the EG+SH treatment group (Fig. 2B).

Histopathological studies

No abnormalities were detected in the kidney tissue of the control group (Fig. 3A). When the kidney tissue of EG group was examined, an excessive level of crystal/stone was seen (Fig. 3B). In the kidney tissues of SH group, very small size and exiguous level of crystal/stone formation were found (Fig. 3C). It was determined that the plant extract of SH administration reduced the formed stones and crystals.

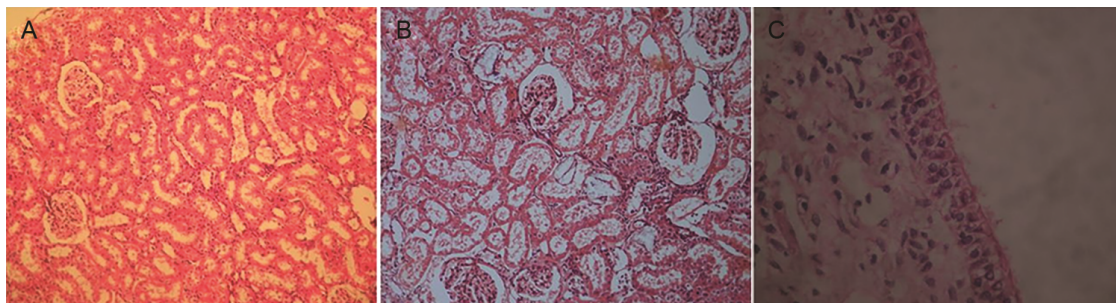


Fig. 3 — Representative light micrographs of kidney tissue in the experimental groups. (A) control group normal tubules in the kidney cortex; (B) Ethylene glycol (EG) group rats with lots of birefringent crystals, desquamation, dilatation, and degeneration, fed with 75% EG; and (C) Normal cortex tubules and glomerulus in the *Scolymus hispanicus* L. (SH) treatment group. [Hematoxylin and Eosin (H&E) staining Magnification, 20X and inset 40X]

Discussion

In the urine, there are substances that cause crystal or stone formation, as well as crystal inhibitory agents such as citrate and magnesium, which inhibit their formation. Stones/crystals seen in kidney stone disease cause damage to epithelial cells in kidney nephrons and also generate free radicals. It has been reported that free radical formation and antioxidant enzymes decrease in this disease process¹¹⁻¹³. Although allopurinol, febuxostat, thiazide diuretics, terpene essential oil preparations, potassium citrate, sodium citrate and corticosteroid have been used for the treatment of renal stone disease, no effective medication has been found yet. Therefore, many herbal medicinal alternatives have been investigated for possible treatment of the disease^{11-13,16}.

The antioxidant effect of *Scolymus hispanicus* L. is (SH) is attributed to its contents viz. tannins, terpenoids and flavonoids. The flowers and leaves of SH have been found to contain α -tocopherol^{17,18}. It has antiarthritic, antibacterial, antiherpetic, anti-inflammatory and antispasmodic effects due to the presence of glycosides, bioactive nitrogen compounds, caffeine, flavanoids, rosmarinic acid and β -carotene. In addition, in colon, kidney and lung cancers, this substance has been reported to have anti-tumoral effects¹⁹.

We observed that during the first 4 weeks of the experiment, calcium levels increased in the EG group and continued to increase until the experiment ended at 8 weeks. The SH treatment resulted in calcium level decrease at the end of experiment; however, the levels were not close to the control group. The increase in calcium levels in the EG group of our study is in agreement with other reported findings^{24,25}.

Magnesium plays a significant role in the inhibition of kidney stone formation by forming soluble magnesium oxalate and excretion of oxalate²⁴. In our study, the EG group showed a significant change in magnesium level after 8 weeks of treatment. On the contrary, treatment with SH for 8 weeks almost reversed the magnesium level similar to the control group. Therefore, therapeutic effect of SH treatment increased the serum levels of magnesium, which contributed to its preventative effect in the formation of kidney stone. Likewise, the increase in phosphorus levels in serum may be considered as a marker for kidney stone formation²⁵. Here, we observed the SH treatment increased the serum phosphorus levels, while in the

EG group it was found to be decreased as compared to the control group.

At the end of the treatment, AST levels of SH group were significantly higher than the EG group ($P < 0.05$) and significantly lower than the control group. In a similar study with the *Spirulina* plant, the decrease of AST levels in the EG group is in accordance with our results¹⁶. In a study conducted with streptozotocin-induced diabetic animals of SH treatment group, AST levels were reported to decrease, but in our study, stability was achieved in AST levels. Experimental diabetic model was used in this study as compared to our study^{21,23}.

Serum ALT levels were significantly increased ($P < 0.05$) in the EG treated groups during the first 4 weeks; but there was a fall after 4 weeks. At the end of the experiment, serum ALT levels of SH group were significantly ($P < 0.05$) higher than the EG group. Furthermore, ALT levels decreased in the EG group after 4 weeks and subsequently fell below the control group levels. In a different study conducted with SH plant, streptozotocin-induced diabetic serum ALT level was found to be decreased, that is similar to our current study^{21,23}.

Although the serum ALP levels of SH treatment group were numerically higher than the EG group, but there was no statistically significant difference. The importance of ALP has been expressed as a marker enzyme in the renal tubular membrane and as an important enzyme for kidney damage. However, its increased level can only be seen when high doses of renal stone-forming substances (*e.g.*, sodium oxalate, *etc.*) are given, which have been demonstrated in other studies²⁶.

Increased level of creatinine, one of the nitrogen-containing compounds in blood, occurs due to the decrease in glomerular filtration with the formation of stones. Accordingly in our study, EG exposure showed significant ($P < 0.05$) increase in the serum creatinine levels consistently. At the same time, the decrease in the SH treatment group stopped at the 4th week of treatment. In other words, the serum creatinine level in the SH treatment group decreased significantly as compared to the EG group ($P < 0.05$). Thus, the lowered creatinine levels by SH treatment can be considered as evidence for improved kidney function.

There was no significant change in oxalic acid level in the control and EG groups during our experiments. Although no stones/crystals were found in the kidney tissues of the treatment group, the oxalic

acid level in the urine samples was high; *i.e.*, SH extract of stones in urine is thought to break. Similar to our study, in a previous report in a group of kidney stones, oxalic acid levels were found increased during the first 3 days and its levels decreased from the 7th day²⁶. Studies on the effects of extracts of red grape seeds and white grape seeds on kidney stones have shown higher oxalic acid levels at the end of first 8 days compared to the control group. In the same study, the amount of oxalic acid in the EG group increased during the first 8 days²⁷.

When the LAP and GGT levels were evaluated at the end of the experiment in urine; there was no significant difference between the groups ($P > 0.05$). These enzymes have been reported to be potential markers in the renal tubular membrane, which are important for kidney damage. Especially in idiopathic CaOx stone formation studies, GGT was found to be higher than the normal levels in urine analysis. This enzyme is considered as a marker of renal proximal tubules damage^{4,26}. In a study where the renal stone was induced by high dose of sodium oxalate (*e.g.* 10 mg/100 g) within the first 24 h, the GGT and LAP levels were reported to be increased; and slightly decreased during the next 7 days²⁶. In our study, we measured these levels only at 4 and 8 weeks of the treatment which showed xxx levels.

When the kidney tissue of the control group was examined, there were no crystals/stones, especially in the renal cortex. Notably, when the different segments of the nephrons were examined in the renal tissue of EG group, there were large amounts of crystals/stones. In the kidney tissues of the SH treatment group, relatively smaller amount of crystal/stone formation was found. This observation suggests that the plant extract of SH treatment reduces the stone/crystals formed in the kidney. We observed that the plant extract could not reach the subepithelial intrapapilla completely. It is also possible that stones were excreted from the kidney and cortex-medulla-subepithelial papilla in order to be removed from the kidney. Therefore, during this period, the stones may obstruct the subepithelial papillae, and therefore the stones may appear more often in this area than in the other areas during the SH treatment process. As a result, the reduction in the levels of stones and crystals formed by the plant extract of SH supports the biochemical findings of our study. In the liver tissues, necrosis was not seen in any of our experimental groups.

Conclusion

Our experimental findings suggest that aqueous extracts of roots and shells of *Scolymus hispanicus* L. may be effective in treating kidney stones, and it could be attributed to the diuretic, anti-inflammatory, and antioxidant effects of the active compounds present in the SH extract. Further studies would be desirable to better clarify the mechanism(s) of treatment and elucidate the renal stone lowering effect of SH and other related phytochemicals.

Acknowledgement

This study was supported by Marmara University, Scientific Research Projects Committee (MU-BAPKO); Project number: 04.2017.mar Approval date: 16.01.2017).

Conflict of interest

All authors declare no conflict of interest.

References

- 1 Das M & Malipeddi H, Antiuro lithiatic activity of ethanol leaf extract of *Ipomoea eriocarpa* against ethylene glycol-induced urolithiasis in male Wistar rats. *Indian J Pharmacol*, 48 (2016) 270.
- 2 Marra G, Taroni F, Berrettini A, Montanari E, Manzoni G & Montini G, Pediatric nephrolithiasis: A systematic approach from diagnosis to treatment. *J Nephrol*, 32 (2019) 199.
- 3 Lieske JC, Rule AD, Krambeck AE, Williams JC, Bergstralh EJ, Mehta RA & Moyer TP, Stone composition as a function of age and sex. *Clin J Am Soc Nephrol*, 9 (2014) 2141.
- 4 Khan SR, Reactive oxygen species, inflammation and calcium oxalate nephrolithiasis. *Transl Androl Urol*, 3 (2014) 256.
- 6 İpekçi T, Ateş E & Akın Y, Genel metabolik değerlendirme. *Derman Tıbbi Yayıncılık*, (2015) 1.
- 7 Portis AJ & Sundaram CP, Diagnosis and initial management of kidney stones. *Am Family Physician*, 63 (2001) 1329.
- 8 Jawalekar S, Surve V & Bhutey A, The composition and quantitative analysis of urinary calculi in patients with renal calculi. *Nepal Med Coll J*, 12 (2010) 145.
- 9 Liakopoulos V, Leivaditis K, Eleftheriadis T & Dombros N, The kidney in space. *Int Urol Nephrol*, 44 (2012) 1893.
- 10 Singh P, Enders FT, Vaughan LE, Bergstralh EJ, Knoedler JJ, Krambeck AE, Lieske JC & Rule AD, Stone composition among first-time symptomatic kidney stone formers in the community. *Mayo Clin Proc*, 90 (2015) 1356.
- 11 Saremi J, Kargar-Jahromi H & Pourahmadi M, Effect of *Malva Neglecta* Wallr on ethylene glycol induced kidney stones. *Urol J*, 12 (2015) 2387.
- 12 Bodakhe KS, Namdeo KP, Patra KC, Machwal L & Pareta SK, A polyherbal formulation attenuates hyperoxaluria-induced oxidative stress and prevents subsequent deposition of calcium oxalate crystals and renal cell injury in rat kidneys. *Chinese J Nat Med*, 11 (2013) 466.
- 13 Golshan A, Hayatdavoudi P, Mousa A, Rad AK, Roshan NM, Abbasnezhad A, Mousavi SM, Pakdel R, Zarei B, Aghaee A, Kidney stone formation and antioxidant effects of *Cynodon*

- dactylon decoction in male Wistar rats. *Avicenna J Phytomed*, 7 (2017) 180.
- 14 Tugcu V, Kemahli E, Ozbek E, Arinci YV, Uhri M, Erturkuner P, Metin G, Seckin I, Karaca C, Ipekoglu N, Altug T, Cekmen MB & Tasci AI, Protective effect of a potent antioxidant, pomegranate juice, in the kidney of rats with nephrolithiasis induced by ethylene glycol. *J Endourol*, 22 (2008) 2723.
 - 15 Sakhaee K, Maalouf NM & Sinnott B, Kidney stones 2012: Pathogenesis, diagnosis, and management. *J Clin Endocrinol Metabolism*, 97 (2012) 1847.
 - 16 York NE, Borofsky MS & Lingeman JE, Risks associated with drug treatments for kidney stones. *Expert Opin Drug Safety*, 14 (2015) 1865.
 - 17 Al-Attar AM, Antilithiatic influence of spirulina on ethylene glycol-induced nephrolithiasis in male rats. *Am J Biochem Biotechnol*, 6 (2010) 25.
 - 18 Marmouzi I, El Karbane M, El Hamdani M, Kharbach M, Naceiri Mrabti H, Alami R, Dahraoui S, El Jemli M, Ouzzif Z, Cherrah Y, Derraji S & Faouzi MEA, Phytochemical and pharmacological variability in Golden Thistle functional parts: Comparative study of roots, stems, leaves and flowers. *Nat Prod Res*, 32 (2017) 2669.
 - 19 Rubio B, Villaescusa L, Diaz A, Fernandez L & Martin T, Flavonol glycosides from *Scolymus hispanicus* L. and *Jasione glutinosa*. *Planta Med*, 61 (1995) 583.
 - 20 Esiyok D, Otlis S & Akcicek E, Herbs as a food source in Turkey. *Asian Pac J Cancer Prev*, 5 (2004) 334.
 - 21 Sari AO, Tutar M, Bilgic A, Baser KHC, Gülmira Ö & Kosar M, Şevketi Bostan (*Scolymus hispanicus* L.) Bitkisini Kültüre Alma ve Seleksiyon Islahı. *Anadolu Ege Tarımsal Araştırma Enstitüsü Dergisi*, 21 (2011) 1.
 - 22 Başer K, Şevketi Bostan (*Scolymus hispanicus* L.). *Bağbahçe Dergisi*, 60 (2015) 30.
 - 23 Kirimer NE, Tunalier Z, Başer KHC & Cingi I, Antispasmodic and spasmogenic effects of *Scolymus hispanicus* L. and taraxasteryl acetate on isolated ileum preparation. *Planta Medica*, 63 (1997) 556.
 - 24 Ozkol H, Tuluçe Y, Dilsiz N & Koyuncu I, Therapeutic potential of some plant extracts used in Turkish traditional medicine on streptozocin-induced type 1 diabetes mellitus in rats. *J Membrane Biol*, 246 (2013) 47.
 - 25 Azaryan E, Malekaneh M, Nejad MS & Haghighi F, Therapeutic effects of aqueous extracts of *Cerasus avium* stem on ethylene glycol-induced kidney calculi in rats. *Urol J*, 14 (2017) 4024.
 - 26 Laroubi A, Touhami M, Farouk L, Zrara I, Aboufatima R, Benharref A & Chait A, Prophylaxis effect of *Trigonella foenum graecum* L. seeds on renal stone formation in rats. *Phytother Res*, 21 (2007) 921.
 - 27 Khan SR, Shevock PN & Hackett RL, Acute hyperoxaluria, renal injury and calcium oxalate urolithiasis. *J Urol*, 147 (1992) 226.
 - 28 Grases F, Prieto RM, Fernandez-Cabot RA, Costa-Bauzá A, Tur F & Torres JJ, Effects of polyphenols from grape seeds on renal lithiasis. *Oxid Med Cell Longev*, 2015 (2015) 813737.