



Antioxidant mediated defensive potency of *Caesalpinia bonducella* nut on Acetaminophen-inebriated spleen and cardiotoxicity: Implications on oxidative stress and tissue morphology in an *In vivo* model

Sangeetha Nithiyandam, Vaishnavi Jaisankar, Manisha Parthasarathy, Ramkumar Katturajan & Sabina Evan Prince*
School of Bio Sciences and Technology, Vellore Institute of Technology, Vellore, Tamil Nadu, India

Received 24 March 2023; revised 31 March 2023

Overdosing on medications can be unintentional or deliberate. Acetaminophen (APAP) is a widely used over-the-counter analgesic and antipyretic drug. APAP overdose can induce spleen and cardiotoxicity apart from hepatotoxicity. Bonduc nut is well-known for its medicinal and therapeutic properties. More scientific data is necessary to be therapeutically relevant. This study examined the effects of Bonduc nut extract (BNE) on APAP-induced spleen and cardiotoxicity in Wistar albino rats. The rats were divided into five groups of six rats each. *In vitro* assays were carried out to analyze antioxidant activity and free radical scavenging activity in aqueous, ethanol, and methanol solvents in Bonduc nut powder. Total phenolic content, DPPH, catalase, and peroxidase activity were used to test antioxidant activity. The rats were euthanized after the study period to examine antioxidant parameters such as superoxide dismutase, catalase, reduced glutathione, and glutathione peroxidase, as well as lipid peroxidation and histopathology of the spleen and heart tissues. Results suggest that compared to other solvents aqueous has better *In vitro* antioxidant ability and the same extract significantly increased the antioxidant and reduced lipid peroxidation followed by restoring the tissue morphology in APAP-induced spleen and cardiotoxicity. The outcome of the study revealed that aqueous BNE has a significant protective efficacy against APAP-induced spleen and cardiotoxicity in Wistar albino rats.

Keywords: Antioxidants, APAP, Bonduc nut, Cardiotoxicity, Free radical scavenging, Spleen injury

N-acetyl-p-aminophenol, also generally known as Acetaminophen or APAP, is a non-prescription analgesic and antipyretic medication that is regarded as safe and effective at therapeutic doses all over the world. Even though APAP has an excellent safety record at therapeutic doses, high doses can cause severe liver poisoning. Adults should take 650 mg to 1000 mg of APAP every 4 to 6 h, not to exceed 4 g per day. The dose for children is 15 mg/kg every 6 h, up to 60 mg/kg each day. At 7.5 g/day to 10 g/day, or 140 mg/kg, toxicity begins¹. One of the most common causes of poisoning is APAP toxicity. APAP overuse or overdose has been linked to organ damage and even death in various studies². The presence of a metabolic enzyme (Cytochrome p450s) in the heart was discovered by Thum and Borlak, who proposed that APAP could be activated metabolically. Though hepatotoxicity from APAP intoxication has been extensively investigated, data on the spleen and cardiotoxicity is limited³.

Oxidative stress occurs when the body's antioxidant defense mechanism is depleted, resulting in lipid peroxidation, cell membrane breakdown, nucleic acid oxidation, and cell damage^{4,5}. Many studies have shown that oxidative stress in various biological organs and systems, such as the kidney, liver, neurological system, and cardiovascular system, is involved in the toxicity of medications and other chemical molecules. As a result, there is a growing interest in exploring the mechanism and usefulness of natural antioxidants in the treatment of toxicity. In recent investigations, a variety of natural plants and food supplements have been employed as antioxidant agents^{6,7}.

Caesalpinia bonducella is a big, thorny shrub that grows in India's hotter and southern regions. Its seed is also known as Fever nut, Bonduc nut, and Nicker nut⁸. It's a massive thorny shrub with hooks and straight, strong yellow prickles on the branches. Bonduc nuts have been used traditionally to treat a variety of symptoms and maladies, including abdominal pain, colic, leprosy, fever, edema, and malaria⁹. In folkloric medicine, the seeds of Bonduc

*Correspondence:
E-mail: eps674@gmail.com

nut are said to have diverse therapeutic properties such as anti-inflammatory, antipyretic, anti-diabetic, anti-periodic, anti-diuretic, anthelmintic, anti-bacterial, anti-convulsant, anti-anaphylactic, anti-diarrheal, antiviral, anti-asthmatic, anti-inflammatory, anti-amoebic and anti-estrogenic effects¹⁰. The seeds contain a good nutrition profile and a bunch of therapeutic properties compared to other parts which are attributable to the presence of phytochemicals such as furan diterpenes, phytosterinin, beta-sitosterol, flavonoids, bonducellin, aspartic acid, arginine, citrulline, and beta-carotene¹¹.

When acetaminophen at a supratherapeutic dose (greater than 4 g/day), is consumed, glucuronidation and sulfation pathways get saturated, thereby higher quantities of APAP are metabolized through the CYP450 pathway¹². As a consequence, producing large amounts of toxic NAPQI which then binds to a range of cellular proteins, in particular mitochondrial proteins, this binding results in 80-90% depletion of GSH functions in the organs and aggregation of these unconjugated NAPBQI in cells progresses to cell death resulting in oxidative stress, ultimately toxicity^{13,14}. So, in the current research, we scrutinized the protective effects of Bonduc nut on APAP-induced spleen and heart toxicity in female Wister albino rats through the biochemical and histopathological evaluation for the prophylactic efficacy of BNE against the adverse effects of APAP overdose on spleen and heart.

Materials and Methods

Drug and chemicals

Bonduc nut seed powder was procured from Jeyam Herbals in Madurai, Tamil Nadu, India. APAP and Silymarin were purchased from Sisco Research Laboratories (SRL), Chennai, India. To administer to animals, all the agents had to be suspended in water free of pathogens. All additional chemicals that were bought and used were of the finest analytical standard.

Extract preparation

Shukla et al method¹⁵ was used to make the seed extract. Using a Soxhlet apparatus, 50 g powder of

Bonduc nut was extracted for 16 h with 500 mL of 95% ethanol. On a rotary flash evaporator, the crude extract was filtered through Whatman paper and the filtrate was evaporated to dryness. The Bonduc nut extracts (BNE) were kept at 4°C in a sterile glass container until needed.

Antioxidant potential, free radical scavenging, and total phenols of Bonduc nut

The ethanolic, methanolic, and aqueous extracts were made by dissolving 10 g of grounded Bonduc nut powder in 100 mL of ethanol, methanol, and distilled water in a separate conical flask and incubating at 25°C for 48 h and 24 h, respectively, with continual shaking. It was then concentrated and kept at 4°C after filtering with Whatman filter paper. All three extracts were serially diluted at the following concentrations: 1:2, 1:4, 1:8, 1:16, and 1:32. Antioxidant activities, such as catalase, peroxidase, DPPH assay, and total phenolic content, were assessed in each extract. The method of Luck was used to determine catalase activity¹⁶, the method of Reddy et al. was used to determine peroxidase activity¹⁷, the method of Blois was used to determine DPPH assay¹⁸, and the singleton *et al.* 1999 method was used to determine total phenolic content.

Experimental animal housing conditions

Wistar albino rats of the female sex (160-190 g) were procured for the research from the Vellore Institute of Technology (VIT) Animal House in Vellore, Tamil Nadu, India. The experimental operating method and use of animals were approved by the VIT, Vellore's intuitional animal ethical committee (VIT/IAEC/17/Feb2020/10) following Indian CPCSEA guidelines. The animals were kept in regular conditions and housed in six cages. The animals were acclimatized for a week before the start of the experiment. Rats were given free access to water and a pellet as food purchased from Hindustan lever Ltd. in Mumbai, India.

Scheme of experiment

The rats were separated into five groups of six rats each and given the following treatment (Table 1). All

Table 1 — Treatment schedule

Groups	Indications	Treatment	Dose	Administration days
I	Normal control	Nil	NA	NA
II	Toxic control	APAP	2 g/kg b.w	8 th day
III	Treatment	Aqueous BNE	300 mg/kg b.w	All 8 days
		APAP	2 g/kg b.w	8 th day
IV	Standard control	Silymarin	100 mg/kg b.w	All 8days
		APAP	2 g/kg b.w	8 th day
V	Drug alone	Aqueous BNE alone	300 mg/kg b.w	All 8 days

drugs or candidates were administered orally via oral gavage and the animals were allowed to fast for 12 h after the last dose of an eight-day treatment period. On the ninth day, they were sacrificed under ether anesthesia. For antioxidant and histological investigation, spleen and heart tissue were obtained.

Appraisal of tissue Antioxidant and lipid peroxidation analysis

The antioxidant parameters superoxide dismutase (SOD), catalase (CAT), reduced glutathione (GSH), glutathione peroxidase (GPx), and Malondialdehyde (MDA) was assessed using spleen and heart homogenate according to the techniques published by^{19,20}.

Microscopic evaluation of tissue morphology

Spleen and heart tissues from rats were rinsed in 0.1M ice-cold PBS and fixed in 10% formalin before being dehydrated, embedded in paraffin wax, and cut into 5 mm thick sections. Tissue sections were then mounted on a slide and stained with hematoxylin (H) and eosin (E) before being observed under an optical microscope for histopathological anomalies, which were documented and photographed.

Statistical analysis and Data Representation

Graph Pad was used to calculate the statistical significance between the groups using a one-way analysis of variance (ANOVA) followed by Tukey's post hoc test. The analysis findings were given as a mean and standard error. Significant was defined as a p-value of less than 0.05.

Results

In vitro antioxidant activity, total phenolic and flavonoid contents of BNE extracts

Figure 1A depicts the activity of BNE on total phenolic content. It has been found that the dilution of (1:2) produces better results than other dilutions in all extracts. Total phenolic content activity decreases as the serial dilution ratio increases. This shows that aqueous BNE has more total phenolic contents than ethanolic and methanolic extracts. In the DPPH assay, in comparison to all other dilutions, the 1:2 dilution showed good activity in all extracts. The activity of the DPPH test is directly related to the serial dilution ratio. Bonduc nut ethanolic extract has higher activity than methanolic extract. However, the aqueous extract

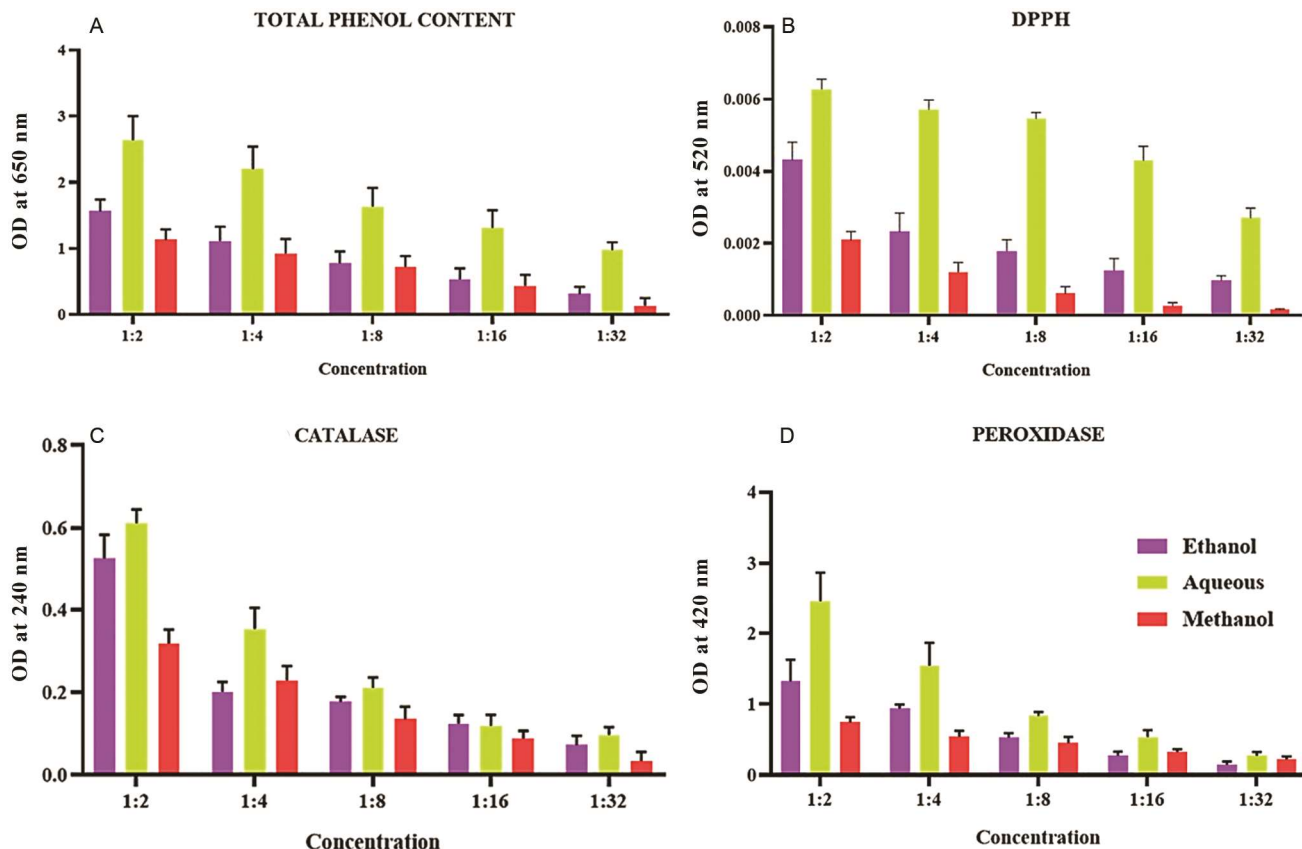


Fig. 1 — *In vitro* antioxidant potential of Bonduc nut. (A) Total phenolic content; (B) Free radical scavenging; (C) Catalase; and (D) Peroxidase

outperformed all other BNE (Fig. 1B). This shows that aqueous BNE has more DPPH scavenging activity than ethanolic and methanolic extracts. The efficacy of BNE on the Catalase assay was shown in (Fig. 1C). When compared to other dilutions such as 1:4, 1:8, 1:16, and 1:32, the sample with a dilution of 1:2 showed potential activity in catalase assay in all extracts. Compared to all other extracts, the aqueous extract had a potential effect. Figure 1D shows the peroxidase activity of the ethanolic, methanolic, and aqueous BNE. With increasing dilution, all of the extracts showed a steady decline in peroxidase activity. The 1:2 dilution showed potential action when compared to all other dilutions. When compared to the other extracts, the aqueous extract performed better.

Repercussions of aqueous BNE on antioxidants and oxidative stress in APAP-induced spleen and cardiotoxicity in rats

APAP-induced SOD levels in the rat's spleen and heart dropped significantly. APAP associated with the BNE-treated group and APAP associated with the

silymarin-treated group elevated SOD levels near normal ranges as in the healthy control group. The BNE-alone treated group had a normal SOD value. The level of SOD activity in the spleen and heart of rats is shown in (Fig. 2A and Fig. 3A). In Groups I and V, the normal range of catalase levels was shown. Catalase levels in the APAP-treated group II were considerably lower. Catalase levels in Groups III and IV had shown almost similar levels to the control group. Group III outperformed group IV which shows their efficacy. The level of catalase activity in the spleen and heart is shown in (Fig. 2B and Fig. 3B). The antioxidant status of GSH in the entire spleen and heart group was evaluated to analyze its level. Group I display the typical normal range. The APAP-induced group showed a significant ($P < 0.05$) decline in level. In the BNE-treated group, GSH levels were restored to almost equal to the normal group. In the Silymarin-treated group, the range was similarly retained however not better than BNE-treated group.

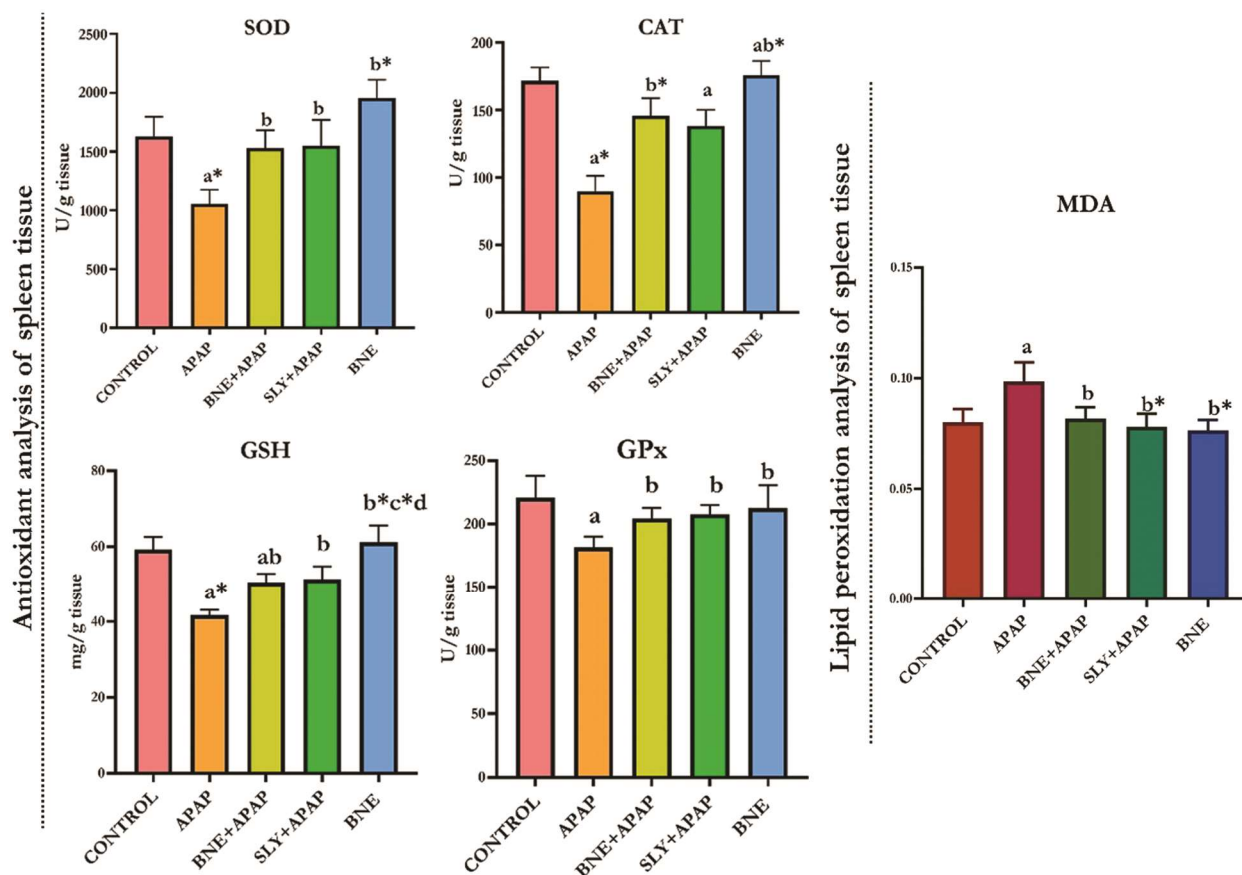


Fig. 2 — Reviving capacity of aqueous BNE against APAP-induced toxicity on rat's spleen antioxidants. Note: "abcd: indicated $P < 0.05$ and "(abcd)*" $P < 0.01$, these variables signify statistical significance. One-way ANOVA was used in the statistical analysis, followed by Tukey's test. (A) group I vs group II, III, IV & V; (B) group II vs group III, IV & V; (C) group III vs group IV & V; and (D) group IV vs group V

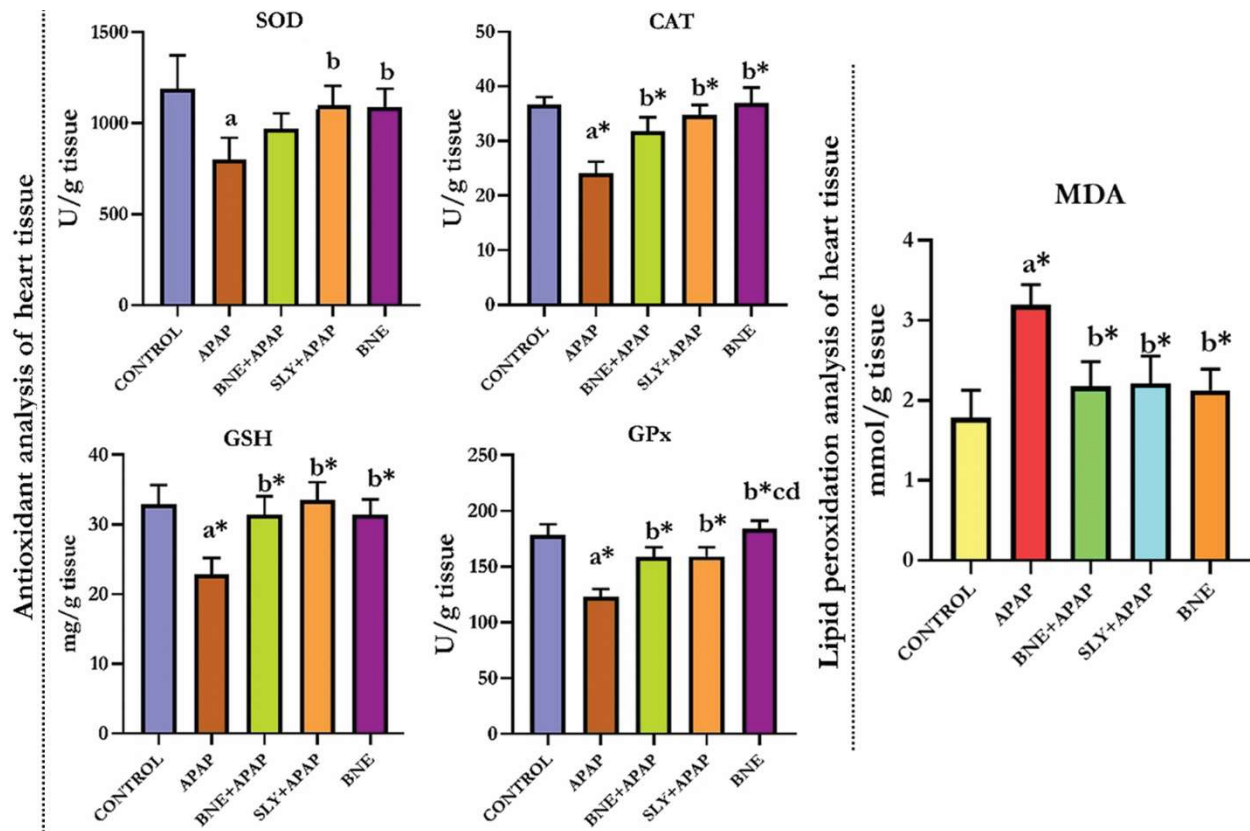


Fig. 3 — Reviving capacity of aqueous BNE against APAP-induced toxicity on rat's heart antioxidants. Note: "abcd: indicated $P < 0.05$ and "(abcd)*" $P < 0.01$, these variables signify statistical significance. One-way ANOVA was used in the statistical analysis, followed by Tukey's test. (A) group I vs group II, III, IV & V; (B) group II vs group III, IV & V; (C) group III vs group IV & V; and (D): group IV vs group V

In the BNE alone treatment group, were maintained as similar to the normal range (Fig. 2C and 3C). Fig. 2D and 3D depicted the levels of GPx in all five groups of spleen and heart samples. Group I show the standard GPx range. The APAP-induced group had shown significantly lower levels. The BNE and silymarin treatment group restored GPx parameters. Both BNE and silymarin are equally effective in GPx. Silymarin also has a better track record of reducing GPx levels. In the BNE-alone treatment group, these levels were maintained.

The lipid peroxidation level in the APAP-treated group was significantly greater than the normal range. Lipid peroxidation in the normal control group was around 1 nmol MDA formed/mg protein, whereas it was five times higher in the toxic group. In the APAP-induced silymarin and BNE treatment group, lipid peroxidation was restored within normal ranges. In the BNE-alone treatment group, remained similar to the normal range. The levels of lipid peroxidation activity in the spleen and heart are shown in (Fig. 2E and Fig. 3E).

Repercussions of aqueous BNE on histopathological alterations in APAP-induced spleen toxicity

The morphology of the spleens of APAP-induced rats showed numerous abnormalities, including white pulp atrophy and lymphoid degeneration. The histoarchitecture of Group I is shown to be normal. The normal splenic parenchyma was found to have been in the APAP-induced along with aqueous BNE-treated group. The white pulp atrophy and lymphoid degeneration were regained in the aqueous BNE-treated group. However, silymarin was unable to recover the lymphoid follicles generated by APAP-induced rats. In the aqueous BNE alone treated group, normal spleen histoarchitecture was seen. The histological tissue of the spleen was shown in (Fig. 4).

Repercussions of aqueous BNE on histopathological alterations in APAP-induced cardiotoxicity

The histopathological assessments of the heart were depicted in (Fig. 5). The morphology of the heart was preserved in the normal control group. The APAP-induced group had localized waviness of the heart and myocardial fiber degeneration. The cardiac

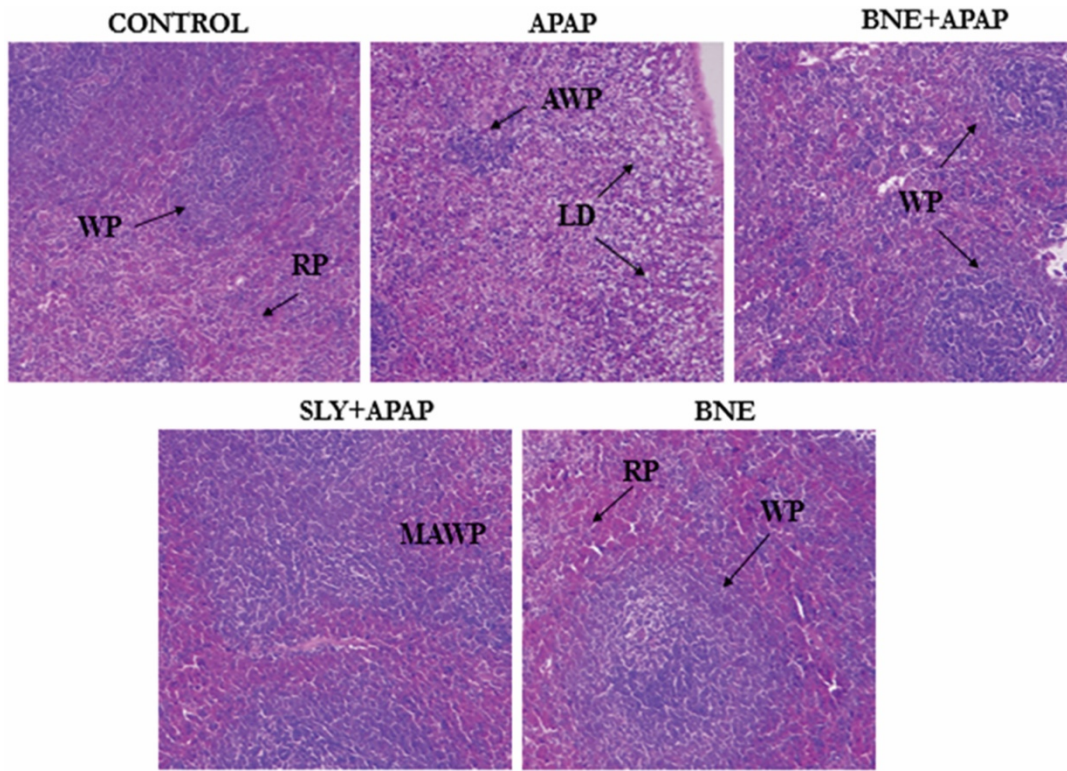


Fig. 4 — Reviving capacity of aqueous BNE against APAP-induced toxicity on rat's spleen tissue architecture

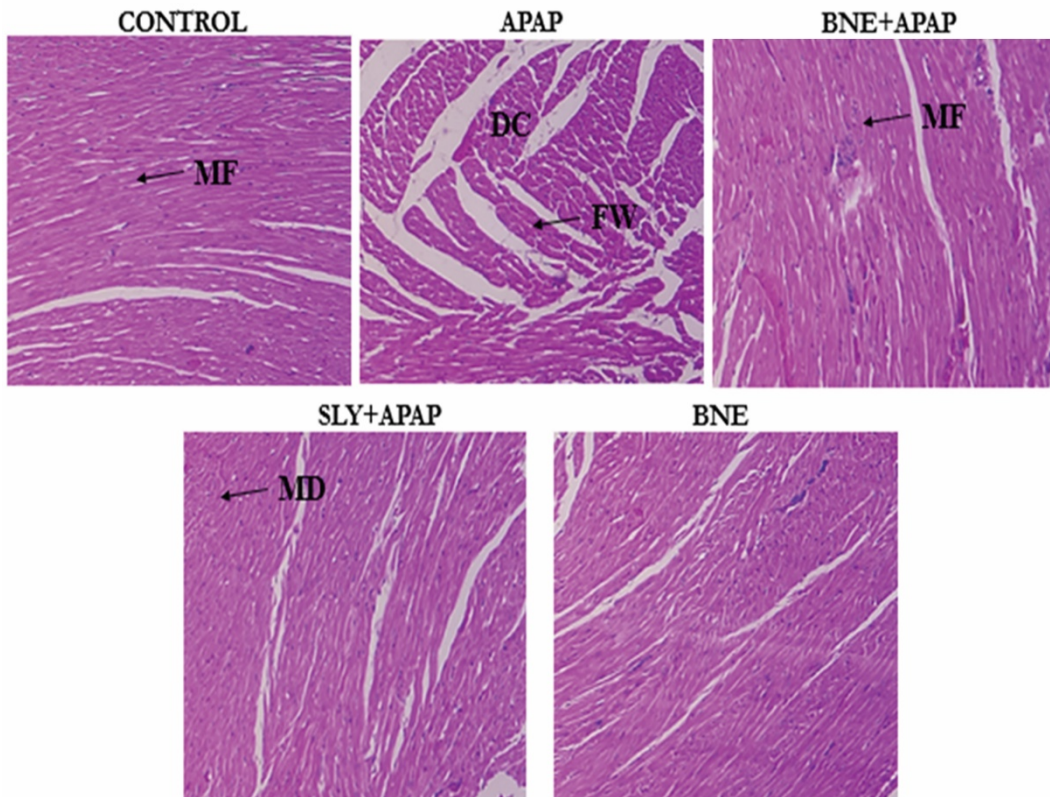


Fig. 5 — Reviving capacity of aqueous BNE against APAP-induced toxicity on rat's heart tissue architecture

morphology of the aqueous BNE-treated group preserved the heart tissue architecture as similar to normal as we observed normal myocardial fibers. Group IV had healthy cardiac fibers with minor damage. BNE-alone treated group shows normal heart histoarchitecture.

Discussion

Overdoses of APAP has been shown to cause oxidative damage, inflammation, and apoptosis, all of which contribute to spleen and heart poisoning^{21,22}. Organ damage results from this process' disruption of cellular homeostasis and induction of tissue necrosis^{23,24}. As a result of glutathione depletion brought on by acetaminophen intoxication, the toxic reactive metabolite NAPQI is produced, which leads to an excessive build-up of toxic metabolites, leaves significant quantities of reactive species unbound, and worsens toxicity. Bonduc nuts have a wide variety of biological activities and therapeutic benefits.

The aqueous BNE showed potential activity in *In vitro* studies such as total phenolic content, DPPH assay, catalase, and peroxidase activity (Fig. 6). In

comparison to all other extracts, the aqueous BNE has demonstrated better potential activity, with a 1:2 dilution showing the best activity. The stable free radical DPPH and total phenolic content aid in the evaluation. Catalase boosts antioxidant properties by protecting living cells from oxidative stress, and it appears to be abundant in our extract as an antioxidant booster²⁵⁻²⁷. Peroxidase is an enzyme involved in the scavenging of reactive oxygen species (ROS), as well as hormone regulation, H₂O₂ detoxication, and lignin biosynthesis^{28,29}. In our study aqueous extract in the dilution, 1:2 shows increased activity in all those parameters when compared to methanol and ethanol extracts. So based on our results we mainly focused on aqueous BNE.

An excessive amount of APAP causes cellular GSH to be depleted. Therefore, GSH's capacity to detoxify NAPQI was diminished. Oxidative damage is mediated by NAPQI elevation. As a result, cellular damage and organ failure are exacerbated. APAP has been shown to cause acute and/or chronic hepatotoxic, nephrotoxic, gastrointestinal problems, splenic enlargement, and cardiotoxicity in several trials. The liver receives 75% of its blood directly

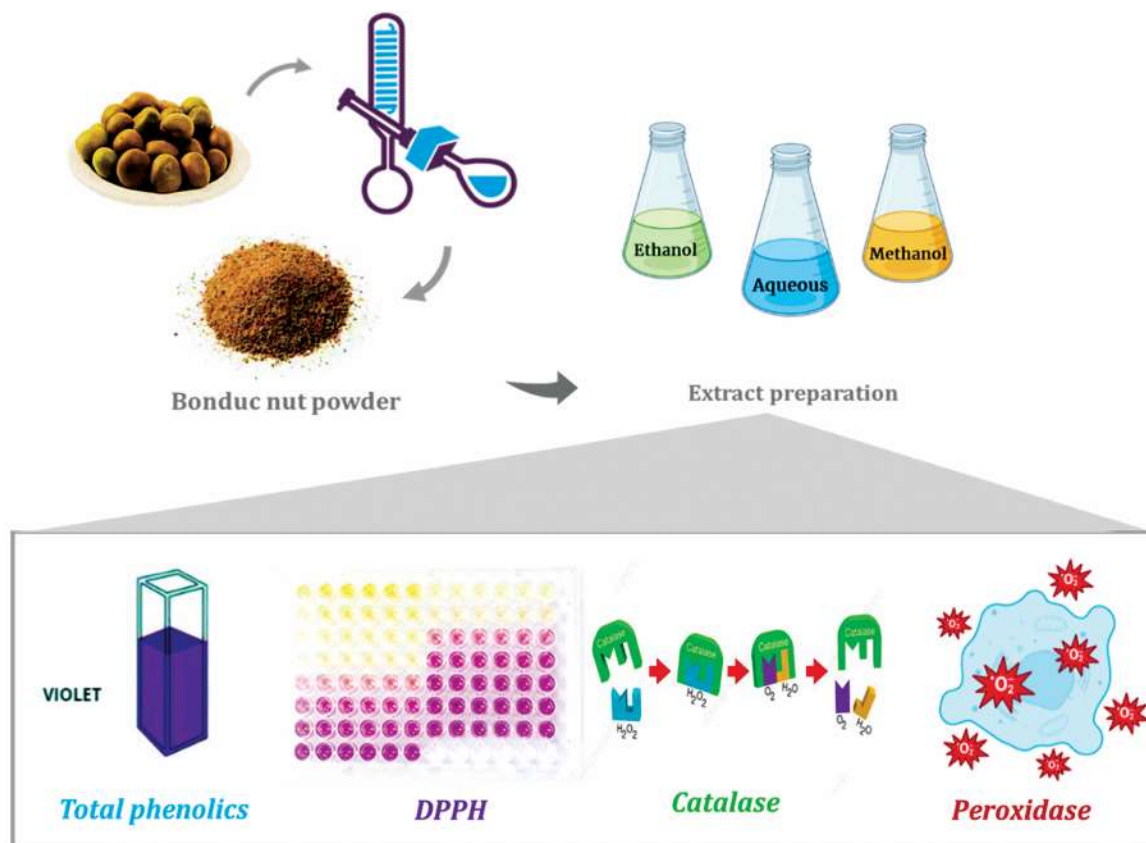


Fig. 6 — Solvent extraction and antioxidant potential of Bonduc nut

from the gastrointestinal tract and portal veins transport medications as foreign substances and xenobiotics in the near-undiluted form to the spleen. Splenic monocytes enter the blood after tissue injury and migrate to inflammatory areas. These splenic monocytes mature into macrophages, which play a role in both pro- and anti-inflammatory responses. Medicinal plants, such as Bonduc nut, may play an important role in the treatment of diseases and as a potential substance for health maintenance. As a result, the biological activities of the Bonduc nut (9 subtribes with 80 more genera than 47 genera) are diverse³⁰.

APAP's major metabolite, NAPQI, is responsible for the production of free radicals by interfering with the body's antioxidant defense mechanism. Free radicals are extremely reactive and can trigger the oxidation of a variety of enzymes¹⁰. After interacting with GSH and lowering its amount in the cell, NAPQI causes cellular injury. As a result, NAPQI weakens the GSH-dependent antioxidant mechanism and increases the generation of free radicals^{14,31,32}. APAP toxicity can result from an increase in intracellular levels of reactive oxygen species (ROS), which are harmful at high concentrations and can interact with macromolecules. The amount of GSH, SOD, CAT, and GPx in the APAP-administered group reduced significantly ($P < 0.05$), but the amount of GSH, SOD, CAT, and GPx improved after using BNE as a pre-treatment. As a result, Bonduc nut could be used as a pre-treatment medication before APAP delivery to prevent APAP-induced toxicity.

Membrane lipids are especially susceptible to free radical destruction. Lipid peroxidation occurs when lipids react with free radicals^{24,33-35}. The synthesis of NAPQI causes lipid peroxidation, which is one of the main causes of APAP-induced toxicity. MDA, a breakdown product of polyunsaturated fatty acid oxidation, is employed as a measure of lipid peroxidation in tissues, and it is the most important factor in oxidative stress. In our study, the quantity of MDA increased significantly following the administration of APAP compared to the control group, but the amount of MDA was reduced by administering BNE for all 8 days as a pre-treatment in group III.

Using BNE as a pretreatment medicine, the spleen and heart had the best results in tissue healing in this investigation. BNE had a protective effect on the spleen and heart, according to the histopathological investigation. The administration of APAP caused tissue damage in the spleen and heart in group II, while in group III, the spleen and heart injuries caused by APAP were neutralized by BNE. Other investigations have already demonstrated the negative effects of APAP on the spleen³⁶ and heart^{37,38}.

The benefits of Bonduc nut were investigated in this study by decreasing APAP-induced oxidative stress, free radicals, and reactive oxygen species produced in the spleen and heart of rats, as well as attenuating APAP-induced antioxidants and tissue morphological alterations (Fig. 7).

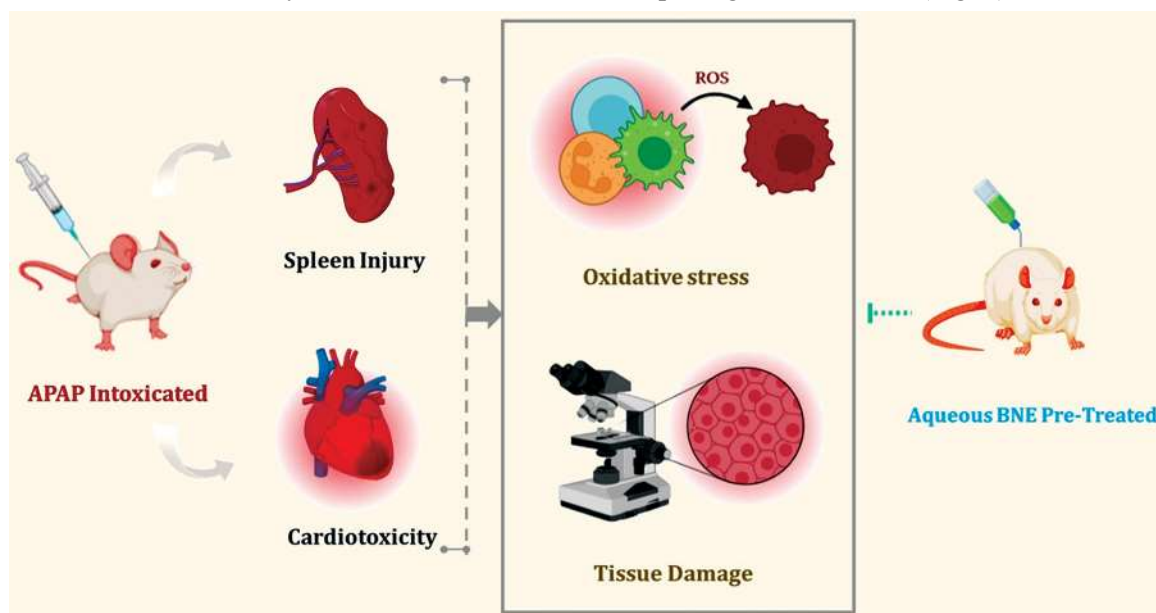


Fig. 7 — Outlining aqueous BNE ability on APAP-intoxicated rats

Conclusion

Our research demonstrated that the aqueous BNE has higher antioxidant activity in *In vitro* than the ethanol and methanol extracts. In APAP-induced spleen and heart damage, oxidative stress was serious. Bonduc nut is a powerful antioxidant that has been shown to protect intoxicated rats from APAP-induced oxidative damage. APAP intoxication resulted in varied degrees of lipid peroxidation, antioxidant enzymes activities depletion, and alterations in histopathological structures of the spleen and heart tissues. In terms of tissue alterations, antioxidant enzyme activity, and oxidative stress, pretreatment with BNE provided near-normal protection. As a result, our research suggests that aqueous BNE could be a promising prophylactic agent against APAP-induced spleen and heart toxicity.

Conflict of interest

All authors declare no conflict of interest.

References

- Agrawal S & Khazaeni B, Acetaminophen Toxicity. *J Nurse Pract*, 3 (2021) 186.
- Abd El-Ghffar EA, Barakat A & Mohamed IK, APAP-induced organ toxicity in rats: The prophylactic role of *Acrocarpus fraxinifolius*. *bioRxiv*, (2018).
- Ralapanawa U, Jayawickreme KP, Mudiyansele E, Ekanayake M & Dissanayake AMSDM, A study on paracetamol cardiotoxicity. *BMC Pharmacol Toxicol*, 1 (2016) 1.
- Katturajan R & Price SE, A role of connexin 43 on the drug-induced liver, kidney, and gastrointestinal tract toxicity with associated signaling pathways. *Life Sci*, (2021) 119629.
- Katturajan R, Mahaboobkhan R, S V & Evan Prince S, Molecular toxicity of methotrexate in rheumatoid arthritis treatment: A novel perspective and therapeutic implications. *Toxicology*, (2021) 152909.
- Blas-valdivia V, Franco-colin M, Pineda-reynoso M & Cano-europa E, An increase of oxidative stress markers and the a - Iteration of the antioxidant enzymatic system are a - ssociated with spleen damage caused by - methimazole-induced hypothyroidism. *Drug and Chemical Toxicology*, 34 (2011) 180.
- Katturajan R & Sabina EP, Joint Inflammation: Insights of Osteoarthritis, Gouty and Rheumatoid Arthritis and its Prevalence, Mechanism, Medications and Remedies. *Indian J Pharm Sci*, 83 (2021) 886.
- Kandasamy V & Balasundaram U, *Caesalpinia bonduc* (L.) Roxb. as a promising source of pharmacological compounds to treat Poly Cystic Ovary Syndrome (PCOS): A review. *J Ethnopharmacol*, 279 (2021) 114375.
- Kannur DM, Antidiabetic and Antihyperlipidemic Activity of *Bonducella* (*Caesalpinia bonducella*) Seeds. *Nuts and Seeds in Health and Disease Prevention*. (2011) 237.
- Pandey D, Kumar A & Jain A, *Caesalpinia bonducella*: A pharmacological important plant. *Pharma Innov J*, 7 (2018) 190.
- Lilaram & Nazeer Ahamed R, Effect of *Caesalpinia bonducella* seed extract on histoarchitecture of some vital organs and clinical chemistry in female albino rats. *J King Saud Univ - Sci*, 25 (2013) 1.
- Caparrotta TM, Antoine DJ & Dear JW, Are some people at increased risk of paracetamol-induced liver injury? A critical review of the literature. *Eur J Clin Pharmacol*, 74 (2018) 147.
- Yoon E, Babar A, Choudhary M, Kutner M & Pysopoulous N, Acetaminophen-Induced Hepatotoxicity: a Comprehensive Update. *J Clin Transl Hepatol*, 4 (2016) 131.
- Nithiyandam S & Prince SE, Toxins mechanism in instigating hepatotoxicity. *Toxin Rev*, 40 (2021) 616.
- Shukla S, Mehta A, Mehta P, Vyas SP, Shukla S & Bajpai VK, Studies on anti-inflammatory, antipyretic and analgesic properties of *Caesalpinia bonducella* F. seed oil in experimental animal models. *Food Chem Toxicol*, 48 (2010) 61.
- Lück H, Catalase. *Methods Enzym Anal*, (1965) 885.
- Reddy KP, Kumar KB, Subhani SM & Khan PA, Effect of light and benzyladenine on dark-treated growing rice leaves (*Oryza sativa*). I. Changes in chlorophyll content and catalase activity. *Physiol Plant*, 63 (1985) 79.
- Blois MS, Antioxidant Determinations by the Use of a Stable Free Radical. *Nature*, 181 (1958) 1199.
- Nishikimi M, Appaji Rao N & Yagi K, The occurrence of superoxide anion in the reaction of reduced phenazine methosulfate and molecular oxygen. *Biochem Biophys Res Commun*, 46 (1972) 849.
- Ohkawa H, Ohishi N & Yagi K, Assay for lipid peroxides in animal tissues by thiobarbituric acid reaction. *Anal Biochem*, 95 (1979) 351.
- Fadda L, Ali HM, Aldrees GA & Alquraishi NM, Nano ubiquinone: Promising candidate for treatment of renal toxicity induced by over dose of paracetamol. *Toxicol Rep*, 6 (2019) 712.
- Song E, Fu J, Xia X, Su C & Song Y, Bazhen Decoction Protects against Acetaminophen Induced Acute Liver Injury by Inhibiting Oxidative Stress, Inflammation and Apoptosis in Mice. *PLoS One*, 9 (2014) e107405.
- Gomaa S, Adverse effects induced by diclofenac, ibuprofen, and paracetamol toxicity on immunological and biochemical parameters in Swiss albino mice. *J Basic Appl Zool*, 79 (2018) 1.
- Uçar B, Huyut Z, Altındağ F, Keleş ÖF & Yildizhan K, Relationship with Nephrotoxicity of Abemaciclib in Rats: Protective Effect of Curcumin. *Indian J Biochem Biophys*, 59 (2022) 963.
- Guengerich FP, Cytochrome P450 2E1 and Its Roles in Disease. *Chem Biol Interact*, 322 (2020) 109056.
- Mankar DG, Gulave BA, Datkhile DK & Zimare BS, Altitudinal gradients influence the accumulation of pharmaceutically important phenolic compounds in the leaves of *Lobelia nicotianifolia* Roth. and regulates its antioxidant and anticancer property. *Indian J Biochem Biophys*, 58 (2021) 253.
- Zohmachhuana A, Vabeiryureilai M, Meitei Thangjam N, Lalrinzuali K, Senthil Kumar N & Kumar A, Antioxidant efficacy and cytotoxicity of ethanol extract of *Clerodendrum infortunatum* against different cell lines. *Indian J Biochem Biophys*, 58 (2021) 572.
- Anderson BJ, Paracetamol (Acetaminophen): Mechanisms of action. *Paediatr Anaesth*, 18 (2008) 915.

- 29 Nghakliana F, Lalmuansangi C, Zosangzuali M, Lalremruati M & Zothansiam, Antioxidative potential and anticancer activity of *Elaeagnus caudata* (Schltdl) against Type-II human lung adenocarcinoma, A549 cells via caspase-mediated apoptotic cell death. *Indian J Biochem Biophys IJBB*, 58 (2021) 543.
- 30 Abd El-Ghffar EA, Barakat A & Mohamed IK, APAP-induced organ toxicity in rats: The prophylactic role of *Acrocarpus fraxinifolius*. *bioRxiv*, (2018).
- 31 Simon Peter J, Nithiyanandam S, Katturajan R, Parthasarathy M, Namachivayam A, Bhaskarmurthy DH & Prince SE, Supplementation of *Madhuca longifolia* Seed oil augments diclofenac-induced organ toxicities: A biochemical and histopathological approach. *Indian J Biochem Biophys*, 60 (2023) 186.
- 32 Parthasarathy M & Prince SE, The potential effect of phytochemicals and herbal plant remedies for treating drug-induced hepatotoxicity: a review. *Mol Biol Rep*, 48 (2021) 4767.
- 33 Araghi A, Golshahi H, Baghban F & Tabari MA, Ameliorative action of farnesol on cyclophosphamide induced toxicity in mice. *J HerbMed Pharmacol*, 7 (2018) 37.
- 34 Nithiyanandam S & Prince SE, *Caesalpinia bonducella* Counteracts Paracetamol-Instigated Hepatic Toxicity via Modulating TNF- α and IL-6/10 Expression and Bcl-2 and Caspase-8/3 Signalling. *Appl Biochem Biotechnol*, (2023) 1.
- 35 Rajkumar R, Ilango B, Vinothkumar K, Savidha R, Senthilkumar S, Ezhilarasan D & Sukumar E, *Moringa oleifera* seeds attenuate benzene-induced alterations in lipid peroxidation and antioxidant enzymes in liver and kidney tissues of Wistar rats. *Indian J Biochem Biophys*, 60 (2022) 26.
- 36 Suttie AW, Histopathology of the Spleen. *Toxicologic Pathology*, 34 (2006) 466.
- 37 Ralapanawa U, Jayawickreme KP, Ekanayake EMM & Dissanayake AMSDM, A study on paracetamol cardiotoxicity. *BMC Pharmacol Toxicol*, 17 (2016) 1.
- 38 Katturajan R, Medha T, Karra SRV & Prince SE, A comparative computational approach on the most deleterious missense variant in Connexin 43 protein and its potent inhibitor analysis. *Indian J Biochem Biophys*, 60 (2022) 7.