



Histological observations on the oocyte development in the Picnic seabream, *Acanthopagrus berda* (Forsskål 1775)

M T Shilta^{*a}, P P Suresh Babu^b, P K Asokan^a, K Vinod^a, I Joseph^c & S Joseph^c

^aCalicut Regional Station of ICAR-Central Marine Fisheries Research Institute, Calicut, Kerala – 673 005, India

^bKarwar Regional Station of ICAR-Central Marine Fisheries Research Institute, Karwar, Karnataka – 581 301, India

^cICAR-Central Marine Fisheries Research Institute, Kochi, Kerala – 682 018, India

*[E-mail: shiltathomas@gmail.com]

Received 27 April 2020; revised 05 February 2022

Histological analysis was carried out on ovarian development in the picnic seabream, *Acanthopagrus berda* (Forsskål 1775) caught in the estuarine waters of Calicut, Kerala, India from January to December 2016. Four developmental phases of oocyte development were identified viz., oogonia proliferation and transformation into the primary oocyte, primary growth phase, secondary growth phase and maturation phase and these are similar to those described for other species. The reproductive development process begins in a very young ovary with the formation of oogonia, the cells originally derived from special primordial germ cells formed early in the embryonic development; their multiplication and differentiation are followed by the release of mature oocytes. Oocyte development stages observed in *A. berda* were chromatin nucleolus, early perinucleolar, late perinucleolar, lipid vesicle stage I oocyte, lipid vesicle stage II oocyte, primary yolk granule stage, secondary yolk granule stage, tertiary yolk granule stage, hydrated oocyte and atretic oocyte. The oocytes entered the maturation phase when they attained the maximum size of $459.6 \pm 71.83 \mu\text{m}$. Histological examination of the mature ovaries showed the presence of all the different oocyte stages in the ovary of *A. berda* with an asynchronous mode of ovarian development shortly before spawning, indicating that the species is a multiple spawner.

[**Keywords:** *Acanthopagrus berda*, Histology, Oogenesis, Ovary]

Introduction

Sustainability of the mariculture industry largely depends on the production of an ample quantity of quality seeds of high-valued marine fishes. Recently, major achievements have been attained in standardizing successful protocols for efficient egg production in hatcheries. However, the main drawback remains in understanding the dynamics of oogenesis in many of the marine teleosts, in which the oocyte passes through various phases of development that are quite complex in different fish species¹.

Oocyte development in teleosts has been widely investigated to elucidate the morphological changes that occur during reproduction. The ovaries of the fishes have been classified into three types according to the pattern of the oocyte development; (i) synchronous ovulation (all the oocytes develop at the same time); (ii) group synchronous ovulation (at least two populations of the oocytes at different developmental stages); and (iii) asynchronous ovulation (different development stages of the oocyte maturation and ovulation takes place in groups)¹.

During the process of oocyte development, yolk globules develop within the oocytes, the cell volume increases, the nucleus moves towards the cell periphery and the micropyle is formed². The process of oocyte development in fishes is quite complex and contains many areas of uncertainty. Studies on oocyte maturation processes, oocyte development in primordial germ-cells, yolk protein precursors, deposition of vitamins in eggs and structure of egg envelopes, have revealed the complexity of oogenesis³. The extracellular matrix reorganization and the theca appear within the follicular cells mainly in layers that surround the oocyte (zona radiata, follicular cells, basement membrane and theca)⁴. The follicular cells together with the mature oocyte form the follicular complex which is important for reproductive function in teleost fishes⁵. However, information regarding the formation of layers in the follicular complex is limited for marine teleosts.

Information on oocyte growth in the picnic seabream, *Acanthopagrus berda* of the family

Sparidae remains limited. *A. berda*, commonly known as the goldsilk seabream or river bream is an estuary-dependent Sparid fish native to India⁶. *A. berda* in tropical Indian waters has a good potential for mariculture^{7,8} due to its recreational value⁹, excellent meat quality¹⁰, market demand, high economic value, ability to tolerate wide variations in both salinity and temperature¹¹, resistance to diseases, adaptability to captivity and fast growth rate¹². Therefore, knowledge of the mechanisms of their oocyte production, its relation to fecundity and possible effects on recruitment may be important to the management of their fishery and farming. Current study investigated the process of oogenesis in *A. berda*, through histological analyses during oocyte maturation.

Materials and Methods

Three hundred and sixty fresh *A. berda* were collected from commercial cast net catches from Korapuzha estuary, Calicut, Kerala, India from January to December 2016. Each fish was cut open and the morphology of the gonad was evaluated for determining sex and maturation stage as reported earlier¹³. The macroscopic study of gonads showed that out of the 360 specimens examined, there were 147 (49 %) females, 118 (39.33 %) males, 10 (3.33 %) transitional and 25 (8.33 %) undifferentiated individuals. The ovaries are classified into seven maturity stages namely, virgin, developing virgin, developing, maturing, mature, running and spent. The ovaries of five fishes from each developmental phase were fixed in neutral buffered formalin. All the tissues were dehydrated in gradient solutions of ethanol and embedded in paraffin. The embedded ovaries were sectioned (5 µm) and rehydrated in ethanol in a stepwise manner. Pieces of ovaries from the posterior, middle and anterior parts were cut separately and subsequently processed for histology. The sections were stained with Harris haematoxylin and eosin in compliance with the accepted procedures¹⁴. The process of oocyte development pattern was investigated by analyzing oocyte diameter progression at different maturity stages. On an average, 150 oocytes were measured per fish. To investigate oocyte composition and size frequency, further 300 – 500 oocytes per fish per development stage were measured and their mean and standard deviation were calculated. The ovarian cell diameter and nuclear sizes were measured using a light microscope (Zeiss Axio Lab A1) at magnifications of X10 and X40.

Different stages of oocytes and their size recorded in each maturity stage of the gonad of *Acanthopagrus berda* are represented in a bar chart using Microsoft excel.

Results

Stages of oocyte development in the ovary of *A. berda*

Four developmental phases of the ovary namely, (a) oogonia proliferation and transformation into a primary oocyte (PO), (b) primary growth phase, (c) secondary growth phase, and (d) maturation phase was recognized during the oocyte development of *A. berda* (Table 1). The primary and secondary growth phases break into series of sub-phases or stages. Ten stages of oocytes namely, chromatin nucleolus stage, early perinucleolar stage, late perinucleolar stage, lipid vesicle stage I oocyte, lipid vesicle stage II oocyte, primary yolk granule stage, secondary yolk granule stage, tertiary yolk granule stage, hydrated oocyte and atretic oocyte were identified in the ovary of *A. berda* at various developing stages (Table 1).

Oogonia proliferation and transformation into a Primary Oocyte (PO)

The observations based on the histology studies revealed that the structural changes occur from primary oocytes residing in oogonial nests. Major stages during the oocyte development include the Primordial Germ-Cells (PGCs) formation followed by the transformation of PGCs into oogonia and subsequently their transformation into primary oocytes, with the onset of meiosis. Oogonia, the smallest cells in the germinal epithelium, present both singly or in small nests are roughly spherical in shape with a centrally located nucleus (Fig. 1) and after mitotic division, they develop into oocytes of subsequent generations.

Primary growth phase

Primary growth phase includes mainly perinuclear oocytes. Histologically, perinuclear oocytes were without yolk and are observed all round the year in all stages of ovarian maturation with dominance observed in virgin, developing virgin and developing stages of ovaries (Table 1; Figs. 2a, b; 3a, b) during the post-spawning season (February – July).

Perinuclear oocytes: Three types of perinuclear oocytes distinguished were the chromatin nucleolar oocytes (Fig. 4a), the early perinuclear oocytes (Fig. 4b) and the late perinucleolar oocytes (Fig. 4c).

Table 1 — Stages of ovary development and maturity categories based on histological criteria for *Acanthopagrus berda*

Maturity stage of ovary	Histological criteria	Oocyte stage	Cellular dimensions (µm)	Nuclear dimensions (µm)	Characteristics
Primary growth phase					
Virgin (I) Developing virgin (II) Developing (III)	Only primary growth oocytes present (Figs. 2a & 3a, b)	Chromatin nucleolus	54.85 ± 16.85	17.85 ± 6.06	Polygonal in shape with a centrally located nucleus (Fig. 4a)
		Early perinucleolar	61.85 ± 15.01	31.35 ± 7.31	Nuclei of oocyte undergo meiosis results in formation of a large nucleus and a small amount of cytoplasm (Fig. 4b)
		Late perinucleolar	89.84 ± 18.44	37.62 ± 8.11	Apperance of small lipid vacuoles within the cytoplasm (Fig. 4c)
Secondary growth phase					
Developing (III) Maturing (IV)	Ovaries with primary and secondary growth (few lipid vesicle and vitellogenic) oocytes (Figs. 2b & 3b)	Lipid vesicle stage I	113.4 ± 17.56	46.12 ± 8.83	Small size lipid vesicles appeared throughout the cytoplasm of oocytes. yolk nucleus start appear near the periphery of the cytoplasm (Fig. 4d)
Maturing (IV)	Ovaries with primary and secondary growth oocytes. Increase in number of lipid vesicle and vitellogenic oocytes (Figs. 2c & 3c)	Lipid vesicle stage II	114.2 ± 18.14	72.2 ± 17.36	Large lipid vesicles were distributed more around the nucleus. Yolk granules appear at this stage at the periphery of cytoplasm (Fig. 4e).
Maturing (IV) Mature (V)	Ovaries with primary growth and secondary growth (lipid vesicle and vitellogenic) oocytes (Figs. 2c, d & 3c, d)	Primary yolk granule	299.6 ± 81.97	96.38 ± 81.97	Yolk appeared as granules, changing to globules, present within and between the lipid droplets. Zona radiata increase in thickness (Fig. 4f).
Maturing (IV) Mature (V)	Ovaries with primary growth and secondary growth (lipid vesicle and vitellogenic) oocytes (Figs. 2c, d & 3c, d)	Secondary yolk granule	384.04 ± 57.2	129.57 ± 20.31	Uniformly distribution of yolk globules and lipid vesicles in cytoplasm. Zona radiata differentiated into zona radiata externa and interna (Fig. 4g)
Maturing (IV) Mature (V) Running (VI)	Ovaries with dominating yolked oocytes; very few primary and lipid vesicle oocytes also present (Figs. 2d, e & 3e)	Tertiary yolk granule	459.6 ± 71.83	81.38 ± 20.8	Increase in the size of vitellogenic substances. The contours of the nucleus were highly scalloped (Fig. 4h).
Maturation phase					
Mature (V) Running (VI)	Ovaries with very few primary growth oocytes and large number of advanced yolked oocytes. All yolk fused, obscuring oocyte nucleus (Figs. 2d, e & 3d, e)	Hydrated oocytes			Oocytes entered the maturation phase when they attained size of 459.6 ± 71.83 µm. Nuclear polarization followed by germinal vesicle breakdown, production of polar bodies and the release of eggs (Fig. 4i).
Follicular atresia phase					
Spent (VII)	Primary growth oocytes with major atresia of partially yolked and advanced yolked oocytes (Fig. 2f)	Atretic oocytes			Post-vitellogenic oocytes after spawning became atretic and resorbed. At the onset of atresia, the zona radiata became convoluted and breakup (Fig. 4j).

- a. *Chromatin nucleolar stage*: The mitotic division of oogonial cells had resulted in chromatin nucleolar stage oocytes. They were polygonal in shape with a centrally located nucleus (Fig. 4a).
- b. *Early perinucleolar stage*: The chromatin nucleolar stage was followed by an early perinucleolar stage where the nuclei of oocytes

had undergone meiosis which resulted in the formation of a large nucleus and a small amount of cytoplasm (Fig. 4b). There was a slight increase in cell size and the chromosomes appeared as short loose scattered threads. There were few nucleoli present at this stage that had been occupying the periphery of the nucleus. As the oocyte grew, the number of nucleoli

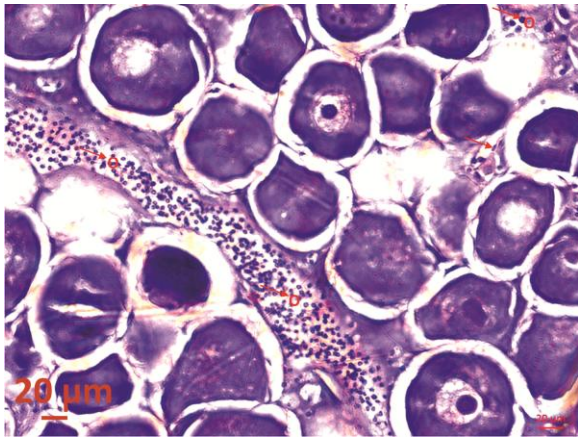


Fig. 1 — Oogonia cells present singly or in small nests in the germinal epithelium (O-oogonia)

increased and a reduction in the nucleus-cell ratio was recorded.

- c. *Late perinucleolar stage*: The oocyte at this stage continued to increase in size and small lipid vacuoles had started appearing within the cytoplasm (Fig. 4c).

Secondary growth phase

Secondary growth phase included lipid vesicle oocytes and vitellogenic oocytes. The lipid vesicle oocytes appeared along with the primary growth oocytes and the vitellogenic oocytes in the developing and maturing ovaries (Figs. 2b, c & 3b, c) observed mainly between July and September, indicating a near-spawning condition. Late vitellogenic oocytes

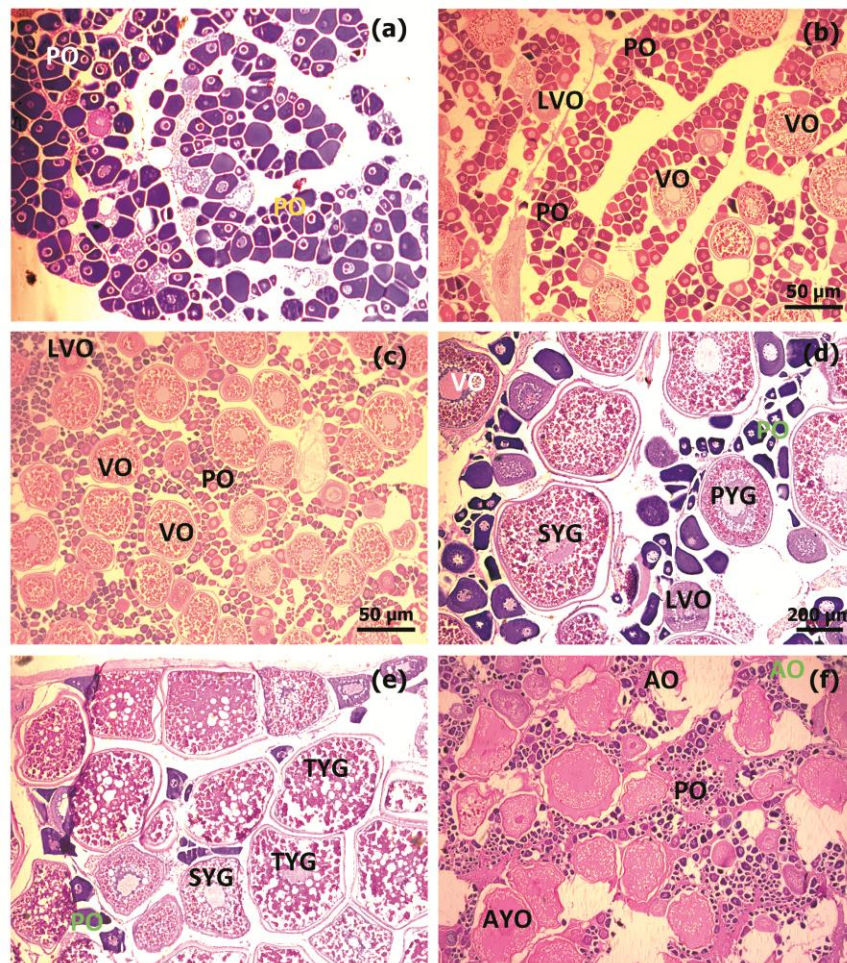


Fig. 2 — Transverse section through a virgin, developing, maturing, ripe, running and spent ovary of a functional female: a) Virgin ovary showing stages of perinuclear oocytes (PO) with no yolk; b) Developing ovary showing dominance of perinuclear oocytes (PO) along with few lipid vesicle oocytes (LVO) and vitellogenic oocytes (VO); c) Maturing ovary showing all stages of oocytes with increased number of vitellogenic oocytes (VO) along with perinuclear oocytes (PO) and lipid vesicle oocyte (LVO); d) Mature ovary showing dominance of vitellogenic oocytes (VO- primary (PYG) and secondary yolk granule oocyte (SYG)) with few perinuclear oocytes (PO) and lipid vesicle oocyte (LVO); e) Running ovary showing dominance of secondary (SYG) and tertiary (TYG) yolk granule oocytes with few perinuclear oocytes (PO); and f) Spent stage with major atresia of partially yolked and advanced yolked oocytes (AYO) along with few perinuclear oocytes (PO)

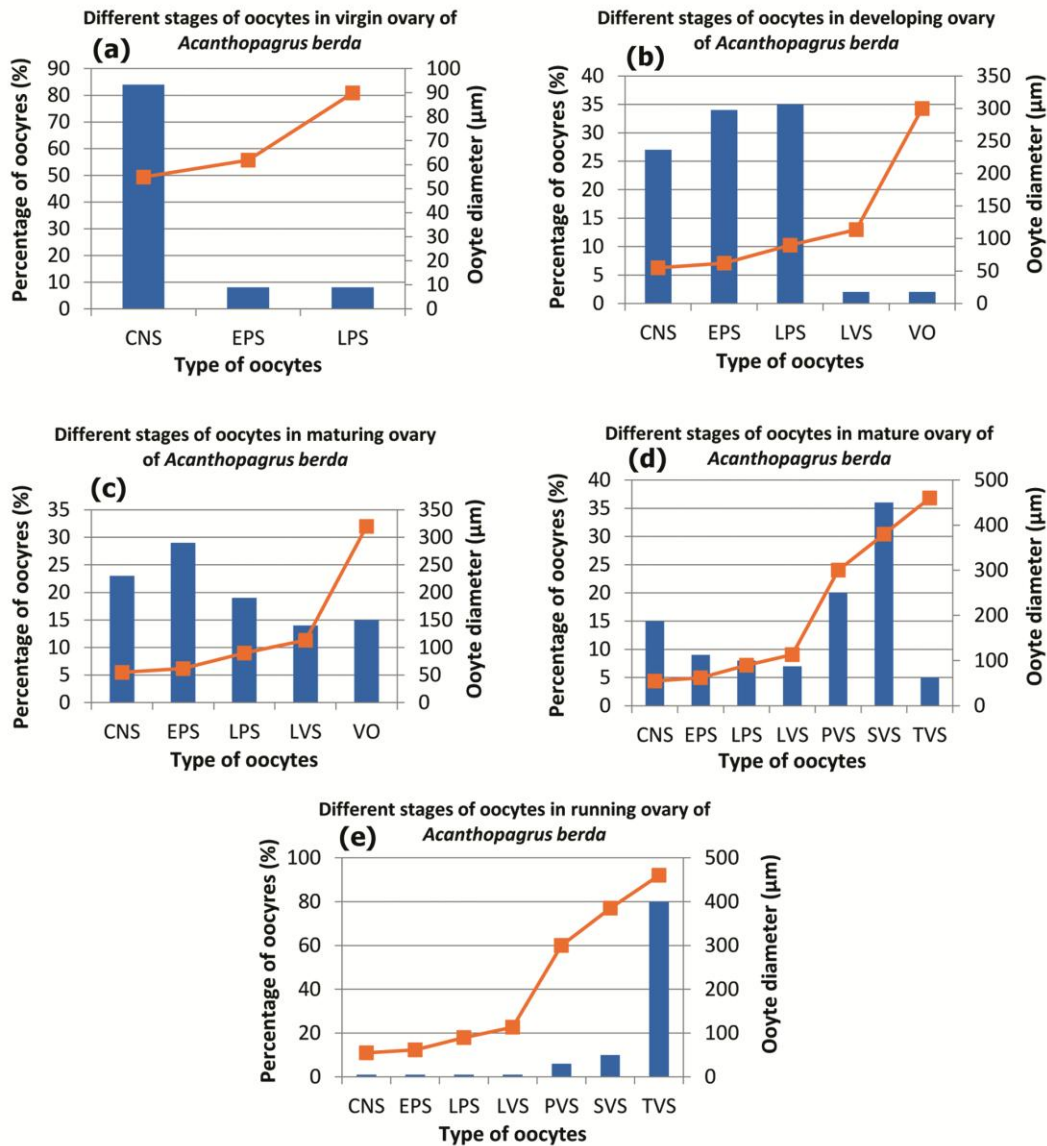


Fig. 3 — Type of oocytes and oocyte size at different stages of ovary development in *Acanthopagrus berda*: a) Virgin ovary showing stages of perinuclear oocytes with no yolk; b) Developing ovary showing dominance of perinuclear oocytes along with few lipid vesicle oocytes and vitellogenic oocytes; c) Maturing ovary showing all stages of oocytes with increased number of vitellogenic oocytes along with perinuclear oocytes and lipid vesicle oocyte; d) Mature ovary showing dominance of vitellogenic oocytes with few perinuclear oocytes and lipid vesicle oocyte; and e) Running ovary showing dominance of secondary and tertiary yolk granule oocytes with few perinuclear oocytes (CNS - Chromatin nucleolar stage; EPS - Early perinucleolus stage; LPS - Late perinucleolus stage, LVS - Lipid vesicles stage, VO - Vitellogenic oocyte, PVS - Primary yolk granule oocyte, SVS - Secondary yolk granule oocyte, TVS - Tertiary yolk granule oocyte)

were dominant in addition to the other early developmental stages of oocytes in the mature and running ovaries (Figs. 2d, e & 3d, e) observed mainly between August and December, indicating a spawning condition.

Lipid vesicle stage I oocyte: At this stage, small size lipid vesicles were appeared throughout the cytoplasm of oocytes (Fig 4d). As the oocytes increased in size, lipid vesicles also increased both in

size and number. The spindle-shaped nucleoli were located at the periphery of the nucleus and the yolk nucleus started appearing near the periphery of the cytoplasm. The granulosa cells began to appear between the theca and plasma membrane in the lipid vesicle stage of the secondary growth phase. Also, the zona radiata became visible for the first time in the lipid vesicle stage oocyte (Fig. 4d, e).

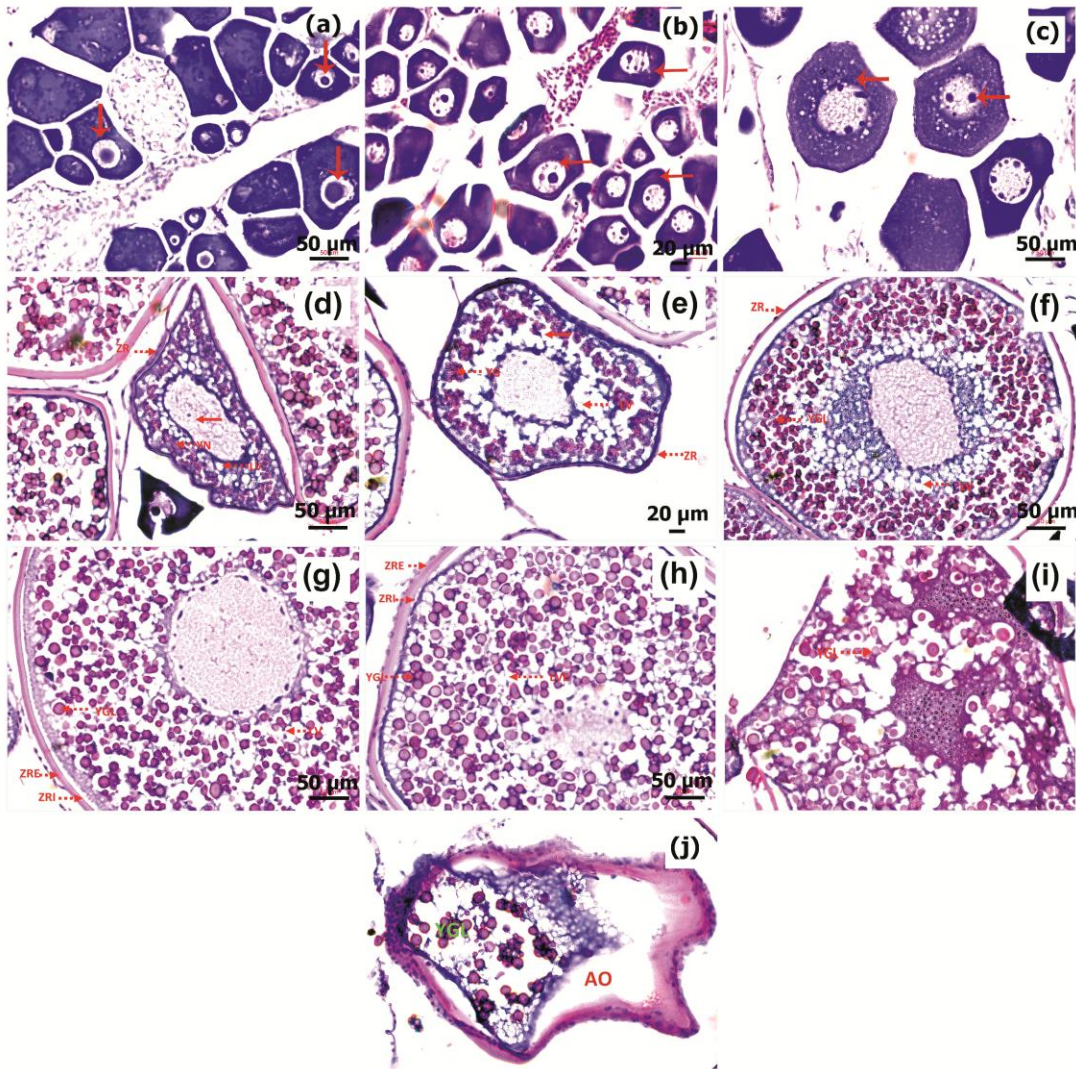


Fig. 4 — Transverse section of the ovary of *A. berda* showing different oocyte stages: a) Chromatin nucleolar stage; b) Early perinucleolus stage; c) Late perinucleolus stage; d) Lipid vesicles stage I; e) Lipid vesicles stage II; f) Primary yolk granule oocyte; g) Secondary yolk granule oocyte; h) Tertiary yolk granule oocyte; i) Migratory nucleus during polarization; and j) Atretic oocyte (YN - Yolk nucleus, YG - Yolk granule, YGL - Yolk globule, LV - Lipid vesicle, ZR - Zona radiata, ZRI - Zona radiata interna, ZRE - Zona radiata externa, AO - Atretic oocyte)

Lipid vesicle stage II oocyte: The number and size of lipid vesicles were increasing continuously at this stage and were distributed in the cytoplasm. Large lipid vesicles were distributed more around the nucleus. The small nucleoli were present at the periphery of the nucleus. Yolk granules began to appear at this stage at the periphery of the cytoplasm (Fig. 4e).

The formation of the follicular epithelial layer or zona granulosa below the theca cells, the appearance of the zona radiata at the oocyte surface between the cytoplasm and the zona granulosa and the formation of yolk granules marks the end of the lipid vesicle

stage and the beginning of the vitellogenesis was observed at this stage.

Primary yolk granule stage: The contours of the nucleus disappeared in this stage. Initially, the yolk appeared as granules, which later changed to globules in the primary yolk granule stage (Fig. 4f). Small, spherical yolk globules measuring about $9.08 \pm 81.97 \mu\text{m}$ had appeared at this stage and were mostly dispersed along the peripheral region of the cytoplasm. Lipid vesicles further increased in number and size and were distributed around the central nucleus. The zona radiata increased in thickness measuring $5.86 \pm 1.51 \mu\text{m}$ at this stage.

Secondary yolk granule stage: There was an increase in the number and size of both yolk globules ($11.36 \pm 2.69 \mu\text{m}$) and lipid vesicles ($12.35 \pm 2.81 \mu\text{m}$) and were uniformly distributed throughout the cytoplasm. The zona radiata underwent further enlargement in thickness ($11.34 \pm 3.28 \mu\text{m}$) and were differentiated into an outer, striated zona radiata externa and a homogeneous inner zona radiata interna (Fig. 4g).

Tertiary yolk granule stage: In the tertiary yolk granule stage, the size of the oocytes had been further increased due to the increase in the size of vitellogenic substances (Table 1 & Fig. 4h). The contours of the nucleus of the tertiary yolk granule stage were highly scalloped and measured $81.38 \pm 20.8 \mu\text{m}$. Both yolk globules ($13.78 \pm 3.81 \mu\text{m}$) and lipid vesicles ($14.19 \pm 3.32 \mu\text{m}$) underwent further enlargement and subsequently covered the nucleolus making them invisible.

Maturation phase

The oocytes entered the maturation phase when they have been attained the maximum size of $459.6 \pm 71.83 \mu\text{m}$. At this phase, the nuclear polarization had taken place followed by germinal vesicle breakdown, production of polar bodies and the release of eggs (Fig. 4i).

Follicular atresia phase

The post-vitellogenic oocytes after spawning became atretic and were resorbed. At the onset of atresia, the zona radiata became convoluted and had started breakup. Both non-bursting and bursting atresia was observed in *A. berda*. Non-bursting atresia (non-ruptured follicular wall) was observed in the early oocytes whereas bursting atresia was observed in the vitellogenic oocytes (Fig. 4j).

Discussion

In the present study, four major stages of oocyte development were identified in *A. berda*. In the majority of teleosts, the process of oogenesis may be divided into four¹⁵, five¹⁶, seven¹⁷ or nine stages¹⁸⁻²⁰. The process of development of the ovary of *A. berda* reported in the present study does not seem to differ greatly from that described by Abou-Seedo *et al.*¹⁸ for *A. latus*. It had been reported that the oocyte development begins with the mitotic division of primary germ cells resulting in oogonia proliferation to form previtellogenic oocytes followed by vitellogenesis, ovulation and extrusion of egg to the

exterior which is similar to most of the teleostean species^{20,21}.

Even though cortical alveoli oocytes were not observed in the present study, lipid-containing vacuoles were observed in pre-vitellogenic oocytes. Dadzei *et al.*²¹ and Abou-Seedo *et al.*¹⁸ also did not observe cortical alveoli oocyte in *Pampus argenteus* and *A. latus*; but, reported the presence of lipid-containing vacuoles in the previtellogenic oocytes. Lipid and yolk granule formation during the vitellogenesis phase of the oocytes are considered as most significant observation during this study. According to Abou-Seedo *et al.*¹⁸, the rhythm of deposition of yolk inclusions in the oocytes differs from species to species, *i.e.*, in some teleosts, both lipid vesicles and yolk granules appear at the same time whereas, in others, lipid vesicle appears first. In the present study, it was observed that lipid droplets appear first in the oocyte followed by the deposition of yolk granules. Similar observations were reported in *A. latus*¹⁸ and *Diplodus puntazzo*²². The amount and sizes of the yolk granules and the lipid droplets were increased with an increase in the size of oocytes. In *A. berda*, lipid yolk is initially developed in the form of discrete vesicles and later with the advancement of oocyte maturation, discrete vesicles become predominant yolk inclusion. The yolk protein is sequestered in the form of yolk globules and they maintain their structural integrity till the maturation. The rhythm of lipid yolk and protein yolk is similar to the pattern of deposition in *P. argenteus*²¹, *Dicentrarchus labrax*²⁰ and *A. latus*¹⁸.

The lipid droplets begin to accumulate in the cytoplasm during the secondary growth phase indicating that the eggs of *A. berda* are pelagic as reported in *Triglia lyra* by Munoz¹⁶. Garratt²³ observed that the live eggs and early larvae of *A. berda* are distinctive from all other seabreams because of the presence of an oil globule that is heavily pigmented with yellow melanophores around its entire surface. At the attainment of the maximum size of $459.6 \mu\text{m}$, the oocyte enters the ovulatory phase in *A. berda*. Whereas, in *Acanthopagrus australis*²⁴ and *A. latus*¹⁸, the oocyte diameter on maturation was $450 \mu\text{m}$ and $375.4 \pm 35.87 \mu\text{m}$, respectively.

The zona radiata layer of the chorion of *A. berda* eggs had shown a progressive increase in their thickness and was differentiated into outer and inner layers as the spawning phase approaches. These changes in zona radiata are probably an adaptation to

overcome the harsh environment at the seabed where incubation and egg development takes place²⁵. According to Abou-Seedo *et al.*¹⁸ the structure of zona radiata of the chorion, differs in complexity, depending on the nature of the substratum where incubation takes place. Garratt²³ had reported the spawning of *A. berda* at night in the estuary in the vicinity of the reefs and the transport of eggs into the marine environment during the peak ebb tides.

Histological examination of the mature ovaries had shown the presence of different oocyte stages in the ovary of *A. berda* shortly before the spawning indicating asynchronous ovulation. It has been reported that in the case of asynchronous ovulation, different development stages of the oocyte maturation and ovulation in groups might be found within the ovaries^{1,26}. The protracted spawning season (August – December) of *A. berda* recorded in our previous study¹³ also indicated the species as a multiple spawner and spawns many times in a year within the spawning season. Earlier reports are evident on the multiple spawning behaviour observed for other sparid species like yellowfin bream, *Acanthopagrus australis*²⁴; saddled bream, *Oblada melanura*¹⁷, gilthead seabream, *Sparus aurata*²⁷; carpenter bream, *Argyrozona argyrozona*²⁸ and sharpnose seabream, *Diplodus puntazzo*²².

Conclusions

From the present study, it can be concluded that the oocyte development of *A. berda* collected from the Indian waters consist of four stages with the following sub-stages: oogonia, chromatin nucleolus stage, early perinucleolar stage, late perinucleolar stage, lipid vesicle stage I oocyte, lipid vesicle stage II oocyte, primary yolk granule stage, secondary yolk granule stage, tertiary yolk granule stage, hydrated oocyte and atretic oocyte. The study also shows the simultaneous presence of oocytes in all stages of development indicating an asynchronous mode of ovarian development in *A. berda*. The information of the present study would be valuable in developing protocols for the efficient egg production of *A. berda* in hatcheries.

Acknowledgements

The authors are grateful to Dr. A. Gopalakrishnan, Director, ICAR-Central Marine Fisheries Research Institute, Kochi, India, for providing facilities, continuous support and encouragement for carrying out this study.

Conflict of Interest

The authors declare that they have no conflict of interest.

Author Contributions

Conceptualization, histology analysis, manuscript writing: MTS; writing - review & editing- PPS; PKA, KV and supervision; review & editing: IJ, SJ.

References

- 1 Yön N D K, Aytekin Y & Yüce R, Ovary maturation stages and histological investigation of ovary of the Zebrafish (*Danio rerio*), *Braz Arch Biol Technol*, 51 (3) (2008) 513-522. <http://dx.doi.org/10.1590/S1516-89132008000300010>
- 2 Viana I K S, Gonçalves L A B, Ferreira M A P, Mendes Y A & Rocha R M, Oocyte growth, follicular complex formation and extracellular-matrix remodeling in ovarian maturation of the imperial zebra pleco fish *Hypancistrus zebra*, *Sci Rep*, 8 (2018) p. 13760. <https://doi.org/10.1038/s41598-018-32117-7>
- 3 Lubzens E, Young G, Bobe J & Cerdà J, Oogenesis in teleosts: How fish eggs are formed, *Gen Comp Endocrinol*, 165 (3) (2010) 367-389. <https://doi.org/10.1016/j.ygcen.2009.05.022>
- 4 Abreu M R, Garcia P & Zaniboni-Filho E, Histological characterization of oocyte developmental stages of suruvi *Steindachneridion scriptum* kept in captivity, *Acta Sci Anim*, 37 (4) (2015) 351–356. <https://doi.org/10.4025/actascianimsci.v37i4.27570>
- 5 Grier H J, Development of the follicle complex and oocyte staging in Red Drum, *Sciaenops ocellatus* Linnaeus, 1776 (Perciformes, Sciaenidae), *J Morphol*, 273 (2012) 801–829. <http://doi.org/10.1002/jmor.20034>
- 6 Shilta M T, Suresh Babu P P, Vinod K, Asokan P K & Joseph I, An account on the morphological identification and molecular confirmation of *Acanthopagrus berda* (Forsskal, 1775) from Malabar Coast, Kerala, India, *Indian J Geo-Mar Sci*, 50 (2) (2021) 156-160. <http://nopr.niscair.res.in/handle/123456789/56315>
- 7 Shilta M T, Chadha N K, Suresh Babu P P, Asokan P K, Vinod K, *et al.*, *Food and feeding habits of goldsilk seabream, Acanthopagrus berda* (Forsskal, 1775), *Turkish J Fish Aquat Sci*, 19 (7) (2018) 605-614. http://doi.org/10.4194/1303-2712-v19_7_07
- 8 Shilta M T, Suresh Babu P P, Vinod K, Asokan P K, Imelda J, *et al.*, *Acanthopagrus berda - a potential species for mariculture in India*, *Mar Fish Infor Ser T&E*, 237 (2018) 20-21.9.
- 9 James N C, Mann B Q, Beckely L E & Govender A, Age and growth of the estuarine-dependent riverbream, sparid *Acanthopagrus berda*, in northern Kwa Zulu-Natal, *South Africa*, *Afr Zool*, 38 (2) (2003) 265-271. <https://doi.org/10.1080/15627020.2003.11407280>
- 10 Anonymous, *Hand book of fisheries statistics of Pakistan: A publication of Marine Fisheries Department, Government of Pakistan*, (Ministry of Food, Agriculture and Cooperatives, Livestock Division), 20 (2012), pp. 215.
- 11 Rahim A, Abbas G, Ferrando S, Gallus L & Ghaffar A, Assessment of growth performance and meat quality of black

- fin sea bream, *Acanthopagrus berda* (Forsskal, 1775) Reared in brackish water ponds: A Preliminary Investigation, *Pak J Zool*, 49 (3) (2017) 869-876. <https://doi.org/10.17582/journal.pjz/2017.49.3.869.876>
- 12 Samuel M & Mathews C P, Growth and mortality of four *Acanthopagrus* species, *Kuwait Bull Mar Sci*, 9 (1987) 159-171.
 - 13 Shilta M T, Suresh Babu P P, Chadha N K, Asokan P K, Vinod K, *et al.*, The annual reproductive cycle and sex inversion of the Picnic seabream, *Acanthopagrus berda* (Forsskal 1775) from Indian waters: Histological and morphometric description, *Aquacult Res*, 00 (2019) 1–15. <https://doi.org/10.1111/are.14246>
 - 14 Gabe M, *Histological techniques*, (Springer, Berlin), 1976, pp. 1106.
 - 15 Arockiaraj A, Haniffa M, Seetharaman S & Singh S, Cyclic changes in gonadal maturation and histological observations of threatened Freshwater catfish “Narikeliru” *Mystus montanus* (Jerdon, 1849), *Acta Ichthyol Piscat*, 34 (2) (2004) 253-266.
 - 16 Munoz M, Sabat M, Mallol S & Casadevall M, Gonadal Structure and Gametogenesis of *Triglia lyra* (Pisces: Triglidae), *Zool Stud*, 41 (4) (2002) 412-420.
 - 17 Zaki M I, Abou-Shabana M B & Assam S S, The reproductive biology of the saddled Bream *Oblada melanura* (L., 1758) from the Mediterranean coast of Egypt, *Oebalia*, 21 (1995) 17-26. <https://www.osti.gov/etdweb/biblio/647259>
 - 18 Abou-Seedo F, Dadzie S & Al-Kanaan K A, Histology of ovarian development and maturity stages in the yellowfin sea bream, *Acanthopagrus latus* (Teleostei: Sparidae) (Hottuyn, 1782) reared in cages, *Kuwait J Sci Eng*, 30 (1) (2003) 121-136.
 - 19 Al-Absawey M A, The reproductive biology and the histological and ultrastructural characteristics in ovaries of the female gadidae fish *Merluccius merluccius* from the Egyptian Mediterranean water, *Afr J Biotechnol*, 9 (17) (2010) 2544-2559. <http://www.academicjournals.org/AJB>
 - 20 Mayer I, Sshaskley S E & Ryland J S, Aspects of the reproductive biology of the bass, *Dicentrarchus labrax* L.I. An histological and histochemical study of oocyte development, *J Fish Biol*, 33 (1988) 609-622. <https://doi.org/10.1111/j.1095-8649.1988.tb05504.x>
 - 21 Dadzie S, Abou-Seedo F & Al-Shallal W, Histological and histochemical study of oocyte development in the silver pomfret, *Pampus argenteus* (Euphrasen) in Kuwait waters, *Arab Gulf J Sci Res*, 18 (2000) 23-31.
 - 22 Pajuelo J G, Lorenzo J M & Domínguez Seoane R, Gonadal development and spawning cycle in the digynic hermaphrodite sharpnose seabream *Diplodus puntazzo* (Sparidae) off the Canary Islands, northwest of Africa, *J Appl Ichthyol*, 24 (1) (2008) 68-76. <https://doi.org/10.1111/j.1439-0426.2007.01010.x>
 - 23 Garratt P A, Spawning of the Riverbream, *Acanthopagrus berda*, in Kosi estuary, *S Afr J Zool*, 28 (1993) 26-31. <https://doi.org/10.1080/02541858.1993.11448284>
 - 24 Cowden K L, *Induced spawning and culture of yellowfin bream, Acanthopagrus australis* (Günther, 1859) and mangrove jack, *Lutjanus argentimaculatus* (Forsskal, 1775), Dissertation, James Cook University, North Queensland, Australia, 1995.
 - 25 Suzuki H I, Agostinho A A & Winemiller K O, Relationship between oocyte morphology and reproductive strategy in Loricariid cat fishes of the Panama River, *Brazil J Fish Biol*, 57 (2000) 791-807. <https://doi.org/10.1111/j.1095-8649.2000.tb00275.x>
 - 26 Nejedli S, Petrinc Z, Ku-ir S & Srebocan E, Annual Oscillation of Ovarian Morphology in European Pilchard (*Sardina pilchardus* Walbaum) in the Northern Adriatic Sea, *Veterinarski Arhives*, 74 (2) (2004) 97-106. <https://hrcak.srce.hr/67812>
 - 27 Ibarra-Zatarain Z & Duncan N, Mating behaviour and gamete release in gilthead seabream (*Sparus aurata*, Linnaeus 1758) held in captivity, *Span J Agric Res*, 13 (1) (2015) 11e04-001, 11. <http://dx.doi.org/10.5424/sjar/2015131-6750>
 - 28 Brouwer S L & Griffiths M H, Reproductive biology of carpenter seabream (*Argyrozona argyrozona*) (Pisces: Sparidae) in a marine protected area, *Fish Bull*, 103 (2005) 258-269. <http://aquaticcommons.org/id/eprint/9612>