

Short Communication

Effect of *Naga Parpam*, a metallic drug of Siddha medicine, on lipid peroxidation, antioxidant enzymes and tissues of liver in Wistar rats

Balakrishnan Ilango^a, Krishnamurthi Vinoth Kumar^b,
Devaraj Ezhilarasan^c & Ethirajan Sukumar^{b,*}

^aDepartment of Pediatrics, Division of Hematology/Oncology/BMT, University of Colorado, Aurora 80045, USA

^bResearch and Development Division, VPro Biotech, Arumparthapuram Main Road, Puducherry (U.T.) 605 110, India

^cDepartment of Pharmacology, Saveetha Dental College and Hospitals, Saveetha Institute of Medical and Technical Sciences (Deemed University), Chennai 600 077, India

*E-mail: drsuku3@gmail.com

Received 04 February 2022; revised 10 January 2024;
accepted 29 April 2024

Naga Parpam (NP), a zinc containing drug is prescribed in Siddha medicine to treat piles, fistula, dysentery, diarrhoea and tuberculosis. In this investigation, NP's effect on lipid peroxidation, antioxidant enzymes and tissues of liver in Wistar rats has been studied. The drug was administered orally in doses of 5, 10 and 20 mg/kg body weight for 28 days to the experimental animals. On day 29, they were sacrificed and the liver was removed. From the liver homogenate, lipid peroxidation (LPO) and the activities of antioxidant enzymes (catalase, superoxide dismutase and glutathione peroxidase) were analyzed. Dose dependent decrease in LPO and increase in the above enzymes revealed its potential antioxidant activity. There were no significant changes in the liver tissue architecture in histology that further confirmed the pro-active role of NP in treating diseases.

Keywords: Antioxidant enzymes, Lipid peroxidation, Liver tissues, *Naga Parpam*, Wistar rats

IPC Code: Int Cl.²⁴: A61K 31/315

Metals are used as drugs to treat diseases similar to proteins, vitamins and essential nutrients¹. In Siddha medicine, metallic drugs are prescribed to treat several chronic diseases since long time. Even metals which exert toxicity, are processed employing specialized traditional techniques that change their properties and render them therapeutically useful². Recent researches have proved that metallic ingredients become nano-

particles after these processes and they easily enter cells and exert desired effect in low concentrations³. Most metallic compounds or their nanoparticles are biocompatible and found in the human tissues where they play a crucial role in the body functions⁴. The metal zinc, its compounds and nano particles are reported to possess preventive and curative properties in preclinical and clinical studies⁵. Recently, in lung cancer patients, zinc supplementation has been found to prevent adverse effects of chemoradiation therapy⁶. In the present study, the effect *Naga Parpam* (NP), a zinc-based formulation of Siddha medicine, on oxidative stress markers in the tissues of liver of Wistar rats was undertaken as sequel to our earlier studies on metallic drugs of Siddha medicine^{7,8}.

Materials and Methods

Naga Parpam prepared as per the procedure mentioned in Siddha literature⁹, was procured from Indian Medical Practitioners' Co-operative Pharmacy and Stores (IMPCOPS), Chennai, India. Male Wistar rats (180-200 g) procured from Tamil Nadu University of Veterinary and Animal Sciences, Chennai and maintained according to the guidelines of Committee for Control and Supervision of Experimental Animals (CCSEA) were used in experiments after obtaining necessary permission from the Institutional Animal Ethics Committee.

Experimental protocol

The animals were randomly divided into five groups, each group contains six animals (n=6). Group I served as the control. NP was orally administered to the remaining groups at doses of 5, 10, and 20 mg/kg, suspended in 1% Carboxymethyl cellulose, over a period of 28 days. These doses were selected based on preliminary investigations. On the 29th day, euthanasia was performed, and the livers were excised, washed with 1% ice-cold saline. Specific amounts of tissue were homogenized and then centrifuged at 3000 rpm for 10 min. The resulting supernatants were utilized to assess lipid peroxidation (LPO), superoxide dismutase (SOD), catalase (CAT), and glutathione peroxidase (GPx) using established methodologies¹⁰⁻¹³. The liver tissue histopathology was examined using hematoxylin and eosin staining¹⁴.

*Corresponding author

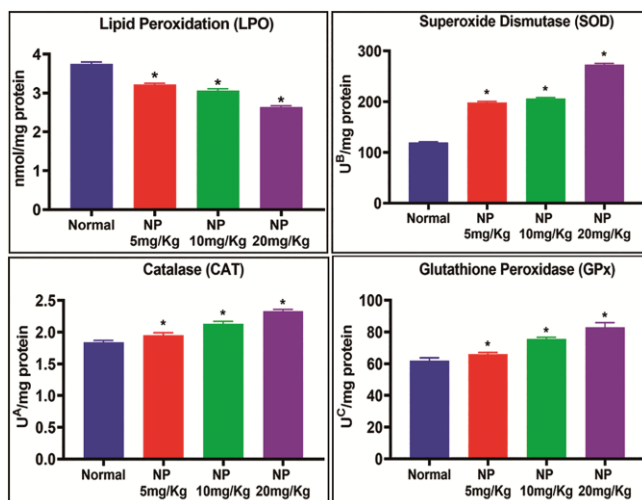


Fig. 1 — Effect of *Naga Parpam* on LPO and antioxidant enzymes. Values represent mean \pm SD of six animals; * $p < 0.05$ when compared to normal animals; LPO: nmol/mg of protein; Catalase: μ moles of H_2O_2 utilized/sec/mg protein; SOD: mg of protein; GPx: μ moles of GSH utilized/minute

Statistical analysis

The data obtained from the experiments were subjected to One-way analysis of variance (ANOVA) followed by Duncan's multiple comparison test (SPSS, 20.0 version). Data presented as the Mean \pm SD for six number of animals. $p < 0.05$ was considered statistically significant.

Results and Discussion

The examination of NP *via* S4 Pioneer Wavelength dispersion X-ray fluorescence Spectrometer (WDXRFS, Bruker-AXS, Germany) indicated Zinc as the predominant component, constituting 65.59% of the substance⁷. Subsequent investigations by other researchers have demonstrated that Zinc is present in NP in the form of zinc oxide nanoparticles¹⁵. In the liver tissues of animals treated with NP, a reduction in lipid peroxidation (LPO) was observed in a dose-dependent manner, while the levels of antioxidant enzymes (CAT, SOD, and GPx) exhibited a gradual increase (Fig. 1). Histological analysis revealed the presence of a small number of apoptotic cells accompanied by mild focal and lobular inflammation (Fig. 2).

As liver is the main target organ for ZnO nanoparticles¹⁶, it was considered to study the changes occurred on it due to chronic administration of NP. The liver is considered a primary source of glutathione production, providing other essential components to the kidney and intestine for the resynthesis of glutathione.

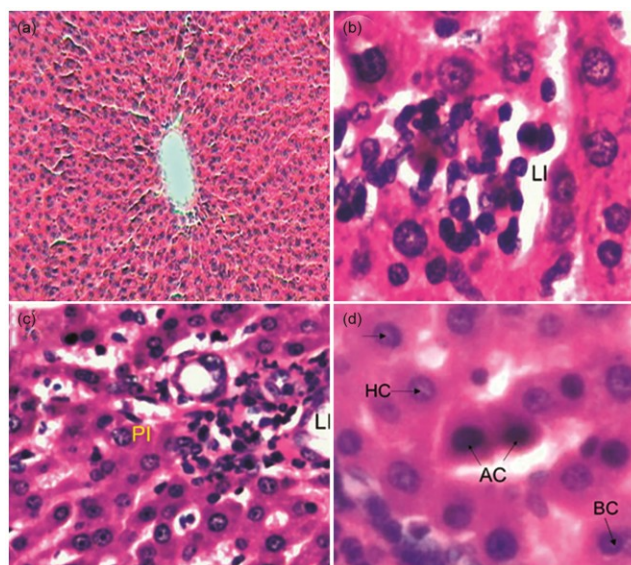


Fig. 2 — Histopathology of liver tissues

- a. Section of tissues of normal rats showing normal hepatocellular architecture
 - b. Section of tissues of *Naga Parpam* (NP) 5 mg/kg dose treated rats showing mild focal lobular inflammation
 - c. Section of tissues of NP 10 mg/kg dose treated rats showing mild periportal and lobular inflammation
 - d. Section of tissues of NP 20 mg/kg dose treated rats showing mild periportal and lobular inflammation
- LI – Lobular Inflammation; PI – Periportal Inflammation; AC – Apoptotic Cells; HC – Hepatic Cells; BC – Binucleated Cells

The intra-hepatic circulation acts as a substrate for GPx, effectively reducing a wide range of hydroperoxides before they can damage unsaturated lipids or transform already existing lipid hydroperoxides into their corresponding compounds. Earlier workers have reported that zinc has anti-peroxidative and metallothionein-inducing capacities besides being an integral part of CuZnSOD, making it a potent antioxidant agent^{17,18}. Moreover, zinc plays a role in preserving the integrity of cell membranes, either through direct mechanisms or indirectly by scavenging free radicals that contribute to elevated LPO. This anti-peroxidative function of zinc appears to be a crucial process through which it reinstates both the structural and functional integrity of the organ. Hence it is construed that zinc helps in maintaining the functional harmony of liver greatly in long-term toxicity by regulating the levels of the drug metabolizing systems¹⁷.

Conclusion

This study showed that the metallic drug NP has significant antioxidant effect on the liver tissues of rats

in the doses studied. This action might be due to the presence of ZnO nanoparticles that were produced during traditional processing methods of raw ingredients. Though nanotechnology is of recent origin, it could be inferred that the Siddhars who evolved the system of medicine several hundred years ago had the knowledge of nanoparticles in drug design.

Conflict of Interest

None to declare

Author Contributions

BI: Experimental studies and data collection; KV: Experimental studies and original draft; DE: Assistance in histopathology studies and manuscript writing; and ES: Conceptualization, guidance and manuscript finalization.

References

- Mahdihassan S, The chemical elements of the human body conceived as pairs of opposites exemplified by calcium-chromium, *Bull Indian Inst Hist Med*, 23 (1) (1993) 49-51.
- Chopra R N, Chopra I C, Handa K L & Kapur L D, Chopra's indigenous drugs of India, Academic Publishers, Calcutta, (1982) p. 461.
- Sudha A, Murty V S & Chandra T S, Standardization of metal-based herbal medicines, *Am J Infect Dis*, 5 (3) (2009) 193-199.
- Ajith M P, Gautam R & Rajamani P, Impact of metal and metal oxide nanoparticles on the male reproductive system: A comprehensive review, *Indian J Biochem Biophys*, 59 (11) (2022) 1048-55.
- Sukumar E, Vinothkumar K & Manickavasagan A, Zinc: Early development, applications, emerging trends, (CRC Press, Florida), 2024, (In Press)
- Cihan Y B & Eser K, Effects of Se, Zn and Cu levels on chemoradiotherapy related toxicity in patients with locally advanced lung cancer, *Indian J Exp Biol*, 60 (5) (2022) 315-321
- Balakrishnan I, Sultan S D, Krishnamurthy V K, Raman R, Subrmanian V, *et al.*, Effect of *Naga Parpam*, a zinc-based *Siddha* medicine, on Hyperlipidemia in rats, *J Complement Integr Med*, 6 (1) (2009) Article 2.
- Ilango B, Kumar K V, Rajkumar R & Sukumar E, Effect of a mercurial drug of *Siddha* medicine on hematological, biochemical and antioxidant status in rats, *Indian J Tradit Know*, 17 (3) (2018) 480-484.
- Anonymous, Formulary of Siddha medicine, (The Indian Medical Practitioners' Co-operative Pharmacy and Stores Ltd., Madras), (1972) p. 12.
- Ohkawa H, Ohisi N & Yagi K, Assay for lipid peroxides in animal tissues by thiobarbituric acid reaction, *Anal Biochem*, 95 (2) (1979) 351-358.
- Kakkar P, Das B & Viswanathan P N, A modified spectrophotometric assay of superoxide dismutase, *Indian J Biochem Biophys*, 21 (2) (1984) 130-132.
- Sinha A K, Colorimetric assay of catalase, *Anal Biochem*, 47 (2) (1972) 389-394.
- Rotruck J T, Pope A L, Ganther H E, Swanson A B, Hafeman D G, *et al.*, Selenium: biochemical role as a component of glutathione peroxidase, *Science*, 179 (4073) (1973) 588-590.
- Suvarna K S, Layton C & Bancroft J D, Theory and practice of histological techniques, (Elsevier B V, Amsterdam, 8th Edition), (2019) p. 126.
- Ramanathan R & Ramasamy R, Characterization of Zinc Oxide based nano Siddha medicine *Naga Parpam* – A potential nutritive supplement in Cancer, *J Pharm Sci Innov*, 8 (3) (2001) 100-104.
- He L S, Yan X S & Wu D C, Age-dependent variation of Zinc-65 metabolism in LACA mice, *Int J Radiat Biol*, 60 (6) (1991) 907-916.
- Dhawan D & Goel A, Further evidence for zinc as a hepatoprotective agent in rat liver toxicity, *Exp Mol Pathol*, 63 (2) (1995) 110-117.
- DiSilvestro R A, Zinc in relation to diabetes and oxidative disease, *J Nutr*, 130 (5S Suppl) (2000) 1509S-1511S. doi: 10.1093/jn/130.5.1509S.